



## Pleomorphic adenoma of the parotid gland in children<sup>☆</sup>

Kimsey H. Rodriguez<sup>a,\*</sup>, Sara Vargas<sup>b</sup>, Caroline Robson<sup>c</sup>,  
Antonio Perez-Atayde<sup>b</sup>, Robert Shamberger<sup>d</sup>, Trevor J. McGill<sup>e</sup>,  
Gerald B. Healy<sup>e</sup>, Reza Rahbar<sup>e</sup>

<sup>a</sup> Department of Otolaryngology, Tulane University Health Sciences Center,  
1430 Tulane Avenue SL-59, New Orleans, LA, United States

<sup>b</sup> Department of Pathology, Children's Hospital, Boston, Boston, MA, United States

<sup>c</sup> Department of Radiology, Children's Hospital, Boston, Boston, MA, United States

<sup>d</sup> Department of Surgery, Children's Hospital, Boston, Boston, MA, United States

<sup>e</sup> Department of Otolaryngology, Children's Hospital, Boston, Boston, MA, United States

Received 9 March 2007; accepted 15 July 2007

Available online 21 September 2007

### KEYWORDS

Pleomorphic adenoma;  
Parotid tumors;  
Pediatrics

### Summary

**Objective:** To evaluate the presentation, imaging characteristics and treatment outcome of pleomorphic adenoma of the parotid in the pediatric population.

**Design:** Retrospective study with institutional review board approval.

**Setting:** Tertiary care pediatric medical center.

**Methods:** An extensive review of medical records with regard to presentation, imaging, histopathology, complication, recurrence and prognosis on patients 18 years or younger presenting from 1983 to 2005.

**Results:** Eleven patients (six females, five males) were identified. The most common presentation was an asymptomatic mass. Preoperative imaging was done on nine patients: MRI ( $N = 6$ ), CT ( $N = 3$ ), ultrasound ( $N = 2$ ), and sialogram ( $N = 1$ ). Initial treatments included: superficial parotidectomy ( $N = 5$ ), total parotidectomy ( $N = 3$ ), excisional biopsy followed by superficial parotidectomy ( $N = 2$ ), and excisional biopsy ( $N = 1$ ). There were two recurrences (18%); one presenting 7 months following excisional biopsy who underwent superficial parotidectomy and one occurred 3 years following total parotidectomy requiring revision parotidectomy and radiation. Other complications included: transient facial nerve paresis ( $N = 5$ ; 45%) and permanent weakness ( $N = 1$ ; 9%). The patients were followed an average of 18 months.

<sup>☆</sup> Presented at ASPO Chicago IL 19 May 2006.

\* Corresponding author. Tel.: +1 504 988 5454.

E-mail address: kimseyrodriguez@hotmail.com (K.H. Rodriguez).

**Conclusions:** Pleomorphic adenoma is one of the most common tumors of the parotid in children. The most common presentation is an asymptomatic mass. A preoperative evaluation with MRI or CT scan can be helpful in determining the extent of the lesion and surgical planning. Complete excision via superficial or total parotidectomy with preservation of facial nerve is the treatment of choice. Long-term follow up is recommended, though was difficult in a tertiary care center.

© 2007 Elsevier Ireland Ltd. All rights reserved.

## 1. Introduction

Parotid neoplasms are rare in the pediatric population. Benign tumors make up 80% of parotid masses. Of these, pleomorphic adenomas, also known as mixed tumors (or benign mixed tumors) are the most common solid parotid tumors in children [1,2]. While pleomorphic adenomas are benign, they have a predilection for recurrence. Additionally, they have the risk of malignant degeneration over time. These properties of pleomorphic adenoma necessitate their accurate diagnosis and appropriate management in children. The purpose of this study is to present our experience with pleomorphic adenoma in children and provide guidelines for their preoperative evaluation and management.

## 2. Materials and methods

Eleven patients aged 18 years and under were treated at Children's Hospital, Boston from 1983 to 2005 for pleomorphic adenoma of the parotid gland. A retrospective chart review, approved by the institutional review board, was performed for these patients. Clinical charts were reviewed with regard to presentation, treatment plan, complications, recurrence and length of follow up. Two patients (patients 1 and 2) were included in a previously published study [3].

Imaging studies were available for review in six patients. The type of imaging modality was noted and the size, location, and characteristics of the lesion were reviewed for each lesion. The differential diagnosis based on imaging characteristics was also noted.

Gross and microscopic pathologic features were reviewed in all cases. Formalin-fixed paraffin-embedded H&E-stained sections were examined histologically. Preoperative fine needle aspiration biopsy results, when obtained, were also reviewed.

## 3. Results

Eleven patients were identified with a histologic diagnosis of pleomorphic adenoma. Patient

demographics are summarized in Table 1. Surgical treatments and follow up for each patient are summarized in Table 2. Nine patients presented for the initial treatment of their parotid mass, while the remaining two patients presented for definitive treatment following histologic diagnosis obtained from their initial procedure at an outside hospital (patients 7 and 11).

The most common presentation was an isolated asymptomatic mass located in the preauricular area, at the angle of the mandible, or tail of the parotid. In patients who presented for initial treatment, the time from onset of the mass to presentation ranged from 2 weeks to 4 years (mean = 42 weeks). No patients presented with facial weakness. Five patients had left-sided masses; the remainder were on the right. There were no bilateral tumors.

### 3.1. Radiographic findings

Preoperative imaging was available for review in six patients. Patient ages at the time of imaging ranged from 10 to 18 years. Imaging studies included ultrasound examination ( $n = 2$ ), magnetic resonance imaging (MR) alone ( $n = 2$ ), and MR and computerized tomography (CT) ( $n = 2$ ). The CT and MR studies included contrast-enhanced images in all patients.

On sonography both tumors appeared sharply circumscribed and hypoechoic. On CT and MR all tumors appeared ovoid or round, mildly lobulated and sharply circumscribed. The CT in one patient revealed a solid, moderately enhancing mass. In the other patient, the mass appeared slightly denser

**Table 1** Patient demographic data

Patient	Age	Sex	Location of tumor
1	15	Female	Right preauricular
2	16	Female	Left tail of parotid
3	16	Male	Left tail of parotid
4	10	Female	Left preauricular
5	13	Male	Right tail of parotid
6	10	Female	Left deep parotid
7	17	Female	Right parotid
8	14	Female	Right preauricular
9	18	Male	Right tail of parotid
10	10	Male	Right preauricular
11	10	Male	Left deep parotid

**Table 2** Surgical treatment and recurrence of tumor

Patient	Treatment outside CHB	Initial treatment at CHB	Recurrence after initial treatment	Subsequent treatment at CHB	Recurrence after final treatment
1		Superficial parotidectomy	No	No	No
2		Excisional biopsy	No	Superficial parotidectomy	No
3		Excisional biopsy	Yes	Superficial parotidectomy	No
4		Superficial parotidectomy	No	No	No
5		Superficial parotidectomy	No	No	No
6		Total parotidectomy with facial nerve sacrifice	Yes	Revision parotidectomy, Radiation therapy	No
7	Incisional biopsy	Superficial parotidectomy	No	No	No
8		Superficial parotidectomy	No	No	No
9		Superficial parotidectomy	No	No	No
10		Total parotidectomy with preservation of facial nerve	No	No	No
11	Excisional biopsy	Total parotidectomy with preservation of facial nerve	No	No	No

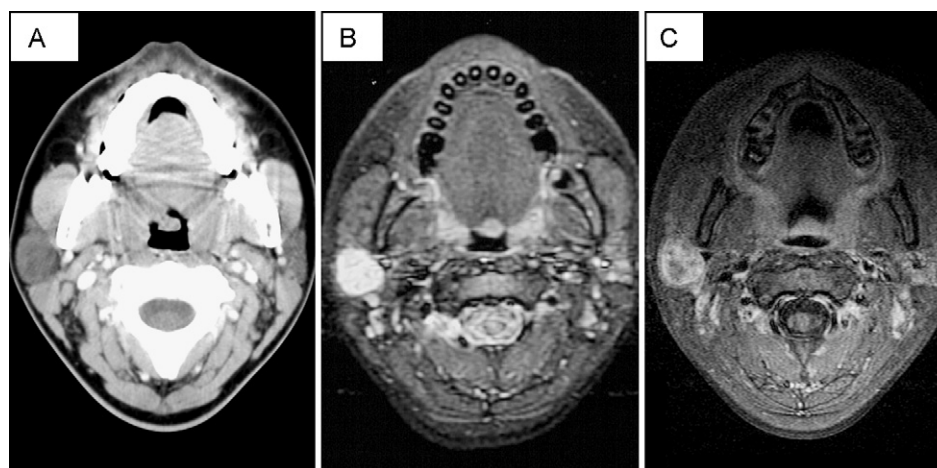
than parotid tissue prior to contrast. Repeat CT was then obtained during the administration of contrast, delayed images were not obtained, and the mass appeared relatively isodense with parotid tissue (Fig. 1). On T2-weighted MR images three tumors appeared markedly hyperintense, the fourth appeared heterogeneous and moderately hyperintense. All tumors enhanced moderately to markedly. There were non-enhancing foci of probably cystic change in two tumors.

The original radiology reports were reviewed. By ultrasound one mass was assessed as being a probable enlarged lymph node. The other mass was reported as being of undetermined etiology. By CT and MR, pleomorphic adenoma was the leading diagnosis in three patients. CTs were read in con-

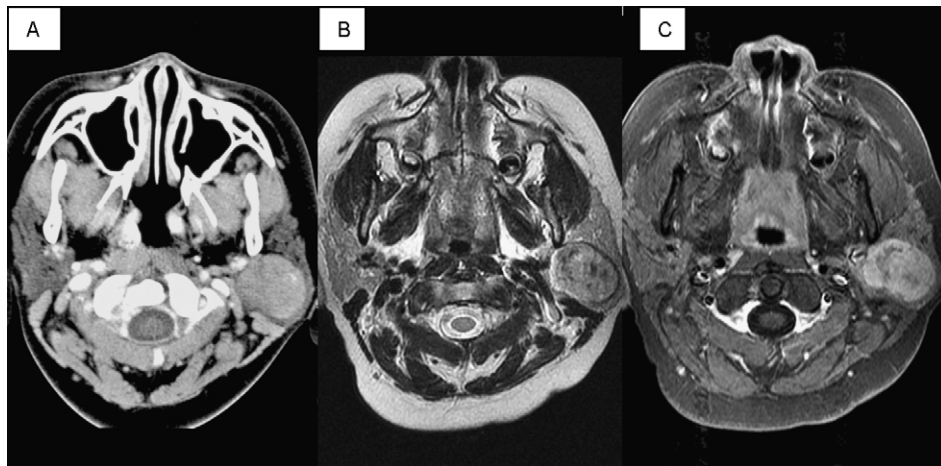
junction with the MRs for both patients for whom both modalities were obtained. The cystic components raised the possibility of infected lymphatic malformation or branchial cleft cyst as a less likely diagnosis in one patient. In the last patient the heterogeneous signal and foci of hypointensity on T2-weighted images resulted in a differential diagnosis of mucoepidermoid carcinoma, schwannoma, rhabdomyosarcoma and pleomorphic adenoma (Fig. 2).

### 3.2. Treatment

All patients underwent surgical treatment for their tumor. Initial surgical treatments performed at Children's Hospital, Boston included the following:



**Fig. 1** Fourteen-year-old girl with a right facial mass. (A) Axial contrast-enhanced CT of the neck acquired during the administration of contrast reveals a hypodense mass in the right parotid gland. (B) Axial fat-suppressed T2-weighted MR image reveals the tumor is slightly lobulated and markedly hyperintense compared with surrounding parotid and lymphoid tissue. (C) Gadolinium-enhanced, fat-suppressed axial T1-weighted MR image demonstrates heterogeneous enhancement with a faintly enhancing peripheral rim.



**Fig. 2** Ten-year-old boy with a left parotid mass. (A) Axial contrast-enhanced CT of the neck acquired during the administration of contrast reveals a homogeneously enhancing mass in the left parotid gland. Punctate hyperdense foci could represent mineralization. (B) Axial T2-weighted MR image reveals that the tumor is moderately heterogeneous and relatively isointense to surrounding parotid and lymphoid tissue. (C) Gadolinium-enhanced, fat-suppressed axial T1-weighted MR image demonstrates heterogeneous enhancement.

superficial parotidectomy ( $N = 6$ ), total parotidectomy ( $N = 3$ ) and excisional biopsy ( $N = 2$ ). One patient who underwent superficial parotidectomy and one who underwent total parotidectomy presented to our facility for definitive treatment following excisional biopsy at an outside facility.

Of the patients who underwent excisional biopsy as their initial procedure, Patient 2 subsequently underwent superficial parotidectomy once the diagnosis of pleomorphic adenoma was made. Patient number 3 underwent excisional biopsy of a discrete nodule at the angle of the mandible. At the time of surgery, the mass grossly appeared to be distinct from the parotid gland, but on histologic section was noted to have tumor involvement of the margins. He developed a recurrence 8 months following the initial surgery and was subsequently treated with a superficial parotidectomy with negative margins.

Of the three patients who underwent a total parotidectomy, two patients had a deep lobe parotid tumor. The third patient (number 6) was 10-year-old with a  $4\text{ cm} \times 3\text{ cm} \times 3\text{ cm}$  tumor intimately involved with the facial nerve. This patient required a nerve graft following sacrifice of the superior branch of the facial nerve.

### 3.3. Pathologic examination

#### 3.3.1. Gross examination

Gross examination of resection specimens showed well circumscribed nodules in 10 patients and an ill-defined nodule in one patient (patient 2) who had undergone a recent incomplete surgical excision. The cut surfaces were tan-white, whorled, and

rubbery to firm. Maximum dimension ranged from 1.6 to 4.7 cm (mean, 2.7 cm; median, 2.0 cm).

#### 3.3.2. Microscopic examination

Microscopic examination revealed benign epithelial/myoepithelial and mesenchymal elements in all cases. In one case (patient 1) a large proportion of the tumor was epithelial; in two cases (patients 8 and 9) myxoid mesenchymal tissue was predominant, and in the remaining eight cases there was a roughly equal admixture of epithelial and mesenchymal elements. The epithelium consisted largely of cords, nests, and acinar/ductular structures comprised of monomorphic cells with bland nuclei. Keratinizing squamous epithelium was also present in a majority of cases. Mesenchymal elements consisted of myxoid stroma, chondroid matrix, and occasionally fat. In the majority of tumors, the lesional boundaries had areas that were poorly defined, with irregular protrusions and apparent discrete "satellite nodules" noted in the sampled planes. The tumor was clear of the resection margin in two patients (patients 3 and 9), present at the surgical resection margin in three patients (patients 4, 6, and 11), and close ( $<1\text{ mm}$ ) to the resection margin in six patients (patients 1, 2, 5, 7, 8, and 10).

Preoperative fine needle aspiration was obtained in two patients. The diagnosis of pleomorphic adenoma was made by fine needle aspiration in both cases.

### 3.4. Follow-up

The most common complication following superficial or total parotidectomy was transient facial

paresis ( $N = 5$ ). All patients with paresis recovered full facial nerve function by their first postoperative visit a week after surgery. One patient (patient 6) underwent sacrifice of the superior branches of the facial nerve with nerve graft repair following resection of the tumor. This patient had recovery of some facial function with noted synkinesis.

Patients were followed for an average of 16.2 months postoperatively. In patients deemed to have a high risk of recurrence (close margins, tumor intimately involved with the nerve) serial MRI's were performed in addition to yearly examination in clinic.

Two patients developed recurrence of their tumor following their initial procedure at Children's Hospital, Boston. The first patient (number 3), as previously mentioned, developed a recurrence 8 months following incomplete surgical excision of a pleomorphic adenoma. He subsequently underwent a superficial parotidectomy with clear resection margins and was free of tumor at last follow-up.

The second patient (number 6) was 10-year-old who developed a recurrence 1 year following a total parotidectomy with facial nerve sacrifice for a large tumor. She was treated with revision parotidectomy and postoperative radiation therapy for treatment of positive margins. She was tumor-free at 109-months follow-up.

### 3.5. Discussion

Tumors of the parotid gland are rare in children. As in the adult population, benign tumors make up the majority of pediatric parotid gland tumors. Most studies list pleomorphic adenoma as the most common benign tumor of the parotid, followed by hemangioma [1].

While relatively rare, pleomorphic adenoma of the parotid gland presents a therapeutic challenge in the pediatric population. Its benign histology dictates removal with an eye toward preservation of the facial nerve. However, its predilection for recurrence and risk of malignant degeneration in a patient population with a long life expectancy requires aggressive treatment.

Pleomorphic adenomas typically present as slow growing, painless masses of the parotid. Untreated, pleomorphic adenomas have a 2–25% risk of malignant degeneration [4,5].

In adults, fine needle aspiration biopsy establishes the diagnosis with good accuracy when sufficient specimen is obtained and a skilled cytopathologist is available [6]. In our series, two patients were diagnosed via fine needle aspiration. However, in children, fine needle aspiration often requires sedation, and has the risk of insufficient

cells for diagnosis. For these reasons, fine needle aspiration is less desirable in the pediatric population. Instead, diagnosis is typically made by surgical excision, usually with the aid of preoperative imaging.

Ultrasonography is a well-tolerated method of evaluating parotid masses in children. It requires no sedation and does not expose the child to radiation. Ultrasound imaging is useful in differentiating solid parotid masses from cystic ones, and for determining intra-parotid versus extra-parotid location. Pleomorphic adenomas have been identified by ultrasound based on their distinct margins and polycyclic shape [7]. However, generally, it has limited usefulness with respect to the diagnosis of and preoperative planning for solid parotid tumors. For this reason, ultrasonography is not commonly used in the preoperative evaluation of a parotid mass.

The most common imaging modalities used in evaluation of parotid masses are CT and MR. While all of the patients in this study were old enough to be examined without the need for sedation, this is a concern in children. Each modality has its strengths and weakness. While CT requires a shorter imaging time and provides excellent spatial resolution, it does expose the patient to ionizing radiation and soft tissue characterization is limited. If images are acquired during the intravenous administration of the contrast bolus, limited delayed images of the mass should be obtained to assess enhancement characteristics. On the other hand, soft tissue characterization of masses is excellent on MR, and there is no exposure to ionizing radiation. However, the examination is costly, more time consuming, and more likely to require sedation in young children. Both modalities are useful in distinguishing between solid and cystic masses and differentiating lymph nodes from parotid parenchymal tumors. The differential diagnosis then is chiefly between pleomorphic adenoma and low grade mucoepidermoid carcinoma.

Imaging characteristics of a pleomorphic adenoma on MR have typically been described as a well-circumscribed tumor that is hyperintense to muscle on T2-weighted imaging. On T1 images the tumor is often hypointense or isointense to muscle. Studies also report that an enhancing capsule on T1 imaging with contrast (seen in two of our patients), and lobulation of the tumor are also predictive of pleomorphic adenoma [8]. In our study, pleomorphic adenoma was suspected based on these imaging characteristics in three of four patients who underwent MR.

Computed tomography findings in pleomorphic adenomas are less distinctive by most reports.

Typically, these lesions are well circumscribed with heterogeneous enhancement with contrast. One study reports that pleomorphic adenomas have increased, homogeneous enhancement with delayed imaging following contrast, which differentiates these tumors from other benign masses [5].

The 11 patients presented herein had pleomorphic adenomas with classic histologic features, including epithelial/myoepithelial cells and a myxochondroid matrix. Other salivary gland neoplasms containing these elements include polymorphous low-grade adenocarcinoma (which almost always arises minor salivary glands) and carcinoma ex pleomorphic adenoma, which can be distinguished from pleomorphic adenoma by their infiltrative borders and/or areas of atypical nuclear morphology, respectively [9]. Because of the irregular margins often noted microscopically and the proximity of the tumor to the facial nerve, we noted difficulty ascertaining clear margins in a large number of patients in this series. Despite the close proximity of these tumors to the surgical margins, there was a low rate of recurrence among our patients.

The risk of recurrence of pleomorphic adenoma is reported to be 20–45% with excisional biopsy [10]. For this reason, preoperative planning is necessary to ensure the appropriate surgical management of the tumor. When pleomorphic adenoma is suspected by imaging or fine needle aspiration, treatment should be geared toward removal of the entire tumor through a superficial parotidectomy for masses superficial to the facial nerve and total parotidectomy with facial nerve dissection for tumors in the deep lobe. With this approach, the risk of recurrence decreases to 2.5–4% [11].

In addition to decreasing the risk of recurrence, superficial parotidectomy also decreases the risk of facial nerve injury. While transient weakness of isolated facial nerve branches approaches 15–25%, the risk of permanent facial paralysis is listed as less than 3% [4,10]. Since pleomorphic adenoma is a benign lesion, sacrifice of the facial nerve is typically not necessary. In our experience, one patient did require sacrifice of a branch of her facial nerve as the nerve traversed the tumor. The remaining patients' tumors were removed while preserving the nerve. This seems to contradict the idea of wide margins to prevent recurrence. However, it is accepted that when tumor abuts the facial nerve, preservation of the nerve by dissecting tumor from the nerve adds only minimal risk of recurrence when a wide margin is obtained in all other planes [10].

The long life expectancy of the pediatric population, combined with documented recurrences up to 30 years after initial resection, makes the risk of recurrence a significant one. When it occurs,

recurrence of pleomorphic adenoma is often difficult to treat since satellite nodules are common. Multiple satellite nodules and previous dissection increase the risk of facial nerve injury [12,13]. In recurrent pleomorphic adenoma, treatment involves revision parotidectomy with an attempt to spare the facial nerve when it is not infiltrated by tumor. If satellite tumors are present, margins are positive or tumor spill is suspected, postoperative radiation therapy is an option.

The use of postoperative radiation therapy for treatment of pleomorphic adenoma is controversial. Many studies show increased control of disease with irradiation [11,12]. However, the side effects of radiation must be weighed against treatment goals for control of a histologically benign tumor. In children, whose facial growth may be retarded with radiation therapy this dilemma becomes more significant. One patient in our study received postoperative radiation following recurrence of her disease. She remains free of tumor 8 years following treatment.

### 3.6. Conclusion

Pleomorphic adenoma of the parotid, while rare in the pediatric population, provides a therapeutic dilemma. While this tumor is benign, recurrence can occur up to 30 years post-treatment. Additionally the risk of malignant degeneration has been established. In children with a long lifespan, these risks are significant. Preoperative evaluation with imaging, or possibly fine needle aspiration, helps in treatment planning for the adequate resection of this tumor. Recurrences, when they happen, are difficult to treat, with increased risk of facial nerve injury and development of subsequent recurrences throughout the patient's lifetime. Often these patients require multiple procedures, with possible radiation therapy for tumor control. Since ninety percent of pleomorphic adenomas occur in the superficial lobe, lateral to the facial nerve, superficial parotidectomy with facial nerve dissection is the treatment of choice for pleomorphic adenoma.

### References

- [1] B.G. Bentz, C.A. Hughes, J.P. Ludemann, J. Maddalozzo, Masses of the salivary gland region in children, *Arch. Otolaryngol. Head Neck Surg.* 126 (2000) 1435–1439.
- [2] R.L. Witt, The significance of the margin in parotid surgery for pleomorphic adenoma, *Laryngoscope* 112 (2000) 2141–2154.
- [3] E.E. Lack, J.P. Upton, Histopathologic review of salivary gland tumors in childhood, *Arch. Otolaryngol. Head Neck Surg.* 114 (8) (1988) 898–906.

- [4] B.E. Hamilton, K.L. Salzman, R.H. Wiggins, H.R. Harnsberger, Earring lesions of the parotid tail, *Am. J. Neuroradiol.* 24 (2003) 157–1764.
- [5] M.H. Lev, K. Khanduja, P.P. Morris, H.D. Curtin, Parotid pleomorphic adenomas: delayed CT enhancement, *Am. J. Neuroradiol.* 19 (1998) 1835–1839.
- [6] E.G. Cohen, S.G. Patel, O. Lin, J.O. Boyle, D.H. Kraus, B. Singh, et al., Fine-needle aspiration biopsy of salivary gland lesions in a selected patient population, *Arch. Otolaryngol. Head Neck Surg.* 130 (2004) 773–778.
- [7] E.J. Bialek, W. Jakubowski, G. Karpinska, Role of ultrasonography in diagnosis and differentiation of pleomorphic adenomas, *Arch. Otolaryngol. Head Neck Surg.* 129 (2003) 929–933.
- [8] K. Ikeda, T. Katoh, S.K. Ha-Kawa, H. Iwai, T. Yamashita, Y. Tanaka, The usefulness of MR in establishing the diagnosis of parotid pleomorphic adenoma, *Am. J. Neuroradiol.* 17 (1996) 555–559.
- [9] G.L. Ellis, P.L. Auclair, *Atlas of Tumor Pathology: Tumors of the Salivary Glands*. Third Series, Fascicle 17, Armed Forces Institute of Pathology, Washington, DC, 1996.
- [10] J. Bullerdiek, G. Wobst, K. Meyer-Bolte, R. Chilla, J. Haubrich, B. Thode, et al., Cytogenetic subtyping of 220 salivary gland pleomorphic adenomas: correlation to occurrence, histological subtype, and in vitro cellular behavior, *Cancer Genet. Cytogenet.* 65 (1) (1993) 27–31.
- [11] E. Stennert, C. Wittekindt, J.P. Klusmann, G. Arnold, O. Guntinas-Lichius, Recurrent pleomorphic adenoma of the parotid gland: a prospective histopathological and immunohistochemical study, *Laryngoscope* 114 (2004) 158–163.
- [12] J.F. Carew, R.H. Spiro, B. Singh, J.P. Shah, Treatment of recurrent pleomorphic adenomas of the parotid gland, *Otolaryngol. Head Neck Surg.* 121 (1999) 539–542.
- [13] J.P. Leonetti, S.J. Marzo, G.J. Petruzzelli, B. Herr, Recurrent pleomorphic adenoma of the parotid gland, *Otolaryngol. Head Neck Surg.* 133 (2005) 319–322.

Available online at [www.sciencedirect.com](http://www.sciencedirect.com)

