

Radiofrequency Ablation of Microcystic Lymphatic Malformation in the Oral Cavity

J. Fredrik Grimmer, MD; John B. Mulliken, MD; Patricia E. Burrows, MD; Reza Rahbar, DMD, MD

Objective: To determine the efficacy and safety of radiofrequency (RF) ablation of vesicles and the resulting symptomatic control of microcystic lymphatic malformation (LM) in the oral cavity.

Design: An institutional review board–approved retrospective study with follow-up telephone interview.

Setting: Tertiary pediatric medical center.

Patients: Eleven children (6 girls and 5 boys), aged 4 to 16 years, presenting between August 1, 2002, and December 1, 2004.

Intervention: Radiofrequency ablation of LM in the oral cavity.

Main Outcome Measures: Symptoms related to LM, postoperative oral intake, and postoperative antibiotic requirements.

Results: Eleven patients presented with microcystic LM involving the lips, tongue, floor of the mouth, or buccal mucosa. Complaints included bleeding, infection, swelling, vesicle formation, and malocclusion. Patients underwent RF ablation (coblation) of oral cavity lesions. Seven (64%) of the 11 patients were able to tolerate oral intake in the recovery room. The need for antibiotics was reduced after RF ablation. All patients related diminished bleeding, pain, infection, or vesicle formation, with more than half reporting a significant improvement (6 patients) or complete resolution (1 patient). Five (62%) of 8 parents stated that the improvement after RF ablation was superior to that following previous procedures.

Conclusions: Subtotal RF ablation of LM appears to be safe, with early postoperative oral intake and minimal postoperative pain. Further studies are needed to determine long-term control of LM.

Arch Otolaryngol Head Neck Surg. 2006;132:1251-1256

Author Affiliations: Division of Otolaryngology, Primary Children's Medical Center, University of Utah, Salt Lake City (Dr Grimmer); and Division of Plastic Surgery, Department of Surgery (Dr Mulliken), and Departments of Radiology (Dr Burrows) and Otolaryngology (Dr Rahbar), Children's Hospital Boston, Harvard Medical School, Boston, Mass.

LYMPHATIC MALFORMATIONS (LMs) are spongelike, abnormally developed lymphatic channels that are present at birth and grow commensurately with the child. Groe-tach¹ theorized that lymphatic channels grow outward from veins, whereas McClure and Sylvester² argued that the lymphatic system develops independently and forms communication with the venous system later in development. Regardless of which theory of lymphatic embryogenesis is correct, LM occurs when there is an abnormal communication with the normal venous drainage system.

The modern nomenclature classifies LM as macrocystic or microcystic on the basis of cyst size. In the head and neck region, macrocystic lesions typically occur below the level of the mylohyoid muscle and are amenable to excision or sclerotherapy.³⁻⁹ Microcystic lesions, on the other hand, are composed of small thin-walled spaces that permeate surrounding soft tissue, making resection difficult and sclero-

therapy ineffective. Complete excision of microcystic LM is not possible without unacceptable morbidity and deformity. Partial or subtotal resection, however, has a high recurrence rate. Recurrence may be due to hydrostatic changes and expansion as inflow of lymph is shunted toward the remaining dilated lymphatic spaces. This may explain the massive enlargement of the tongue often seen after resection of LM in other areas of the head and neck. Recurrence may also be due to sprouting of truncated lymphatic channels. This lymphangogenesis is shown by new vesicle formation on mucosal surfaces and the presence of LM in areas that were previously disease free.

Radiofrequency (RF) ablation is an attractive method for treating microcystic LM in the oral cavity because it destroys tissue at low temperatures (40°C-70°C) with minimal damage to adjacent tissues. Theoretically, the reduced thermal energy and destruction of tissue may diminish regrowth of residual malformation and may also improve wound healing. Two

Table. Preoperative and Postoperative Patient Data

| Patient No./Sex/Age, y | Previous Procedures (Frequency) | Site | Preoperative Condition (Frequency) | Postoperative Condition (Frequency) | Follow-up, mo | Result* |
|------------------------|--|---|--|---|---------------|---------|
| 1/F/9 | Sclerotherapy (2), excision (3) | Upper lip | Infections, swelling, vesicles, and bleeding (several times a year) | Infections less frequent and severe | 15 | ++ |
| 2/F/16 | YAG laser (2) | Oral tongue | Infections, bleeding, vesicles, swelling, and pain (several times a year); unable to close mouth | Able to close mouth; no change in other symptoms | 23 | + |
| 3/F/8 | Neck dissection (4), OK-432 injection (3), laser (3) | Oral tongue, BOT, vallecula, epiglottis | Infections with hemorrhage requiring blood transfusions (every few years); constant oozing | No major bleeding; less oozing | 14 | + |
| 4/M/4 | None | Oral tongue | Persistent vesicles with intermittent infections and swelling | Smaller vesicles | 14 | + |
| 6/F/6 | Excision | FOM, oral tongue | Persistent vesicles with bleeding and pain; major infections (a few times each year) | Fewer vesicles; no major infections | 13 | ++ |
| 7/M/6 | Excision (2), 1% sodium tetradecyl sulfate injection | Buccal mucosa, cheek | Persistent vesicles; biting lesion; infections (every 1-3 mo) | Smaller vesicles; no infections | 6 | ++ |
| 8/M/10 | Excision, laser | Upper and lower lips, submandibular gland, mandible | Repeated bleeding with intermittent infection and swelling | Asymptomatic | 28 | ++ |
| 9/M/16 | None | Oral tongue | Persistent vesicles; swelling during URIs | Asymptomatic | 20 | +++ |
| 11/F/11 | Neck dissection, tracheotomy, partial glossectomy | BOT, oral tongue, vallecula, FOM | Episodic infections associated with vesicles, swelling, bleeding, and pain | Smaller vesicles; infections (1-2 times a year); constant pain and oozing | 24 | + |
| 12/M/9 | Excision (2), sclerotherapy | Left buccal cheek, lip | Persistent vesicles with intermittent swelling; crossbite deformity | No vesicles; crossbite requiring orthodontic therapy | 5 | ++ |
| 15/F/8 | None | Oral tongue | Infections associated with swelling and pain (>once a month) | Less-frequent infections (once a month) | 8 | ++ |

Abbreviations: BOT, base of the tongue, FOM, floor of the mouth; URIs, upper respiratory tract infections.

*Degree of improvement in bleeding, infection, vesicle formation, and pain as rated by the parents, who chose between 5 possible answers: worse, no change, slight improvement (+), significant improvement (++), or resolution of symptoms (+++).

methods have been described for ablation of tissue by RF energy. In the first, a bipolar electrode is inserted directly into the tissue, where the current density creates heat and subsequent tissue destruction. Several passes of the electrode are typically needed to ablate the deeper soft tissue while the superficial mucosal layer is preserved. During a 4- to 6-week period, the damaged tissue contracts with reduction of volume. This method has been used in the head and neck to reduce tissue in the base of the tongue,¹⁰ the palate,¹¹ and the inferior turbinate.¹²

In the second method of ablation, bipolar RF energy is applied in a conductive medium, such as isotonic sodium chloride solution, creating a plasma field. The ionized particles in this field acquire enough energy to break chemical bonds and the tissue dissolves.¹³ The handpiece or "wand" that creates the plasma field also aspirates the dissolved tissue. Ablation proceeds from a superficial to a deep plane, destroying the mucosal surface as the wand is applied directly to the tissue. This

method of RF ablation (also called *coblation*) has been used for tonsillectomy¹⁴⁻¹⁶ and was the method used in our study.

We hypothesized that RF energy can be used effectively for partial excision of LM in the oral cavity, thus reducing symptoms of bleeding, infection, pain, and vesicle reformation.

METHODS

The study group consisted of children evaluated at Children's Hospital Boston who had received a diagnosis of intraoral LM and were treated with RF ablation. Patient medical records were reviewed for the location of the lesions, previous treatment received, presenting symptoms, complications, and findings at follow-up. Sixteen patients were treated between August 1, 2002, and December 1, 2004. Five patients were excluded because their follow-up was shorter than 5 months (n=4) or they could not be contacted to complete the questionnaire (n=1). Of the remaining 11 patients, there were

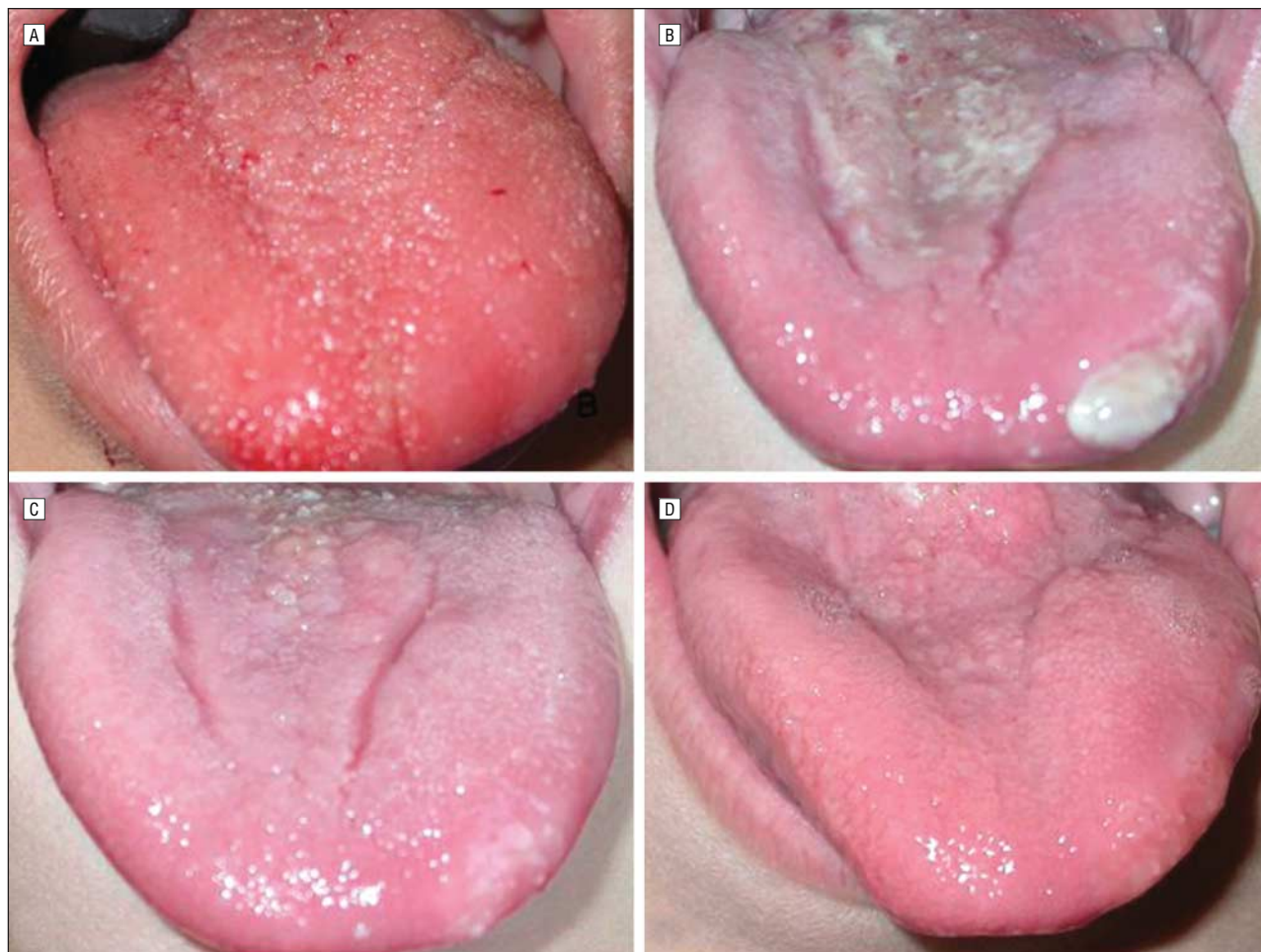


Figure 1. Microcystic lymphatic malformation of the anterior tongue. This patient underwent subtotal radiofrequency (RF) ablation of the mucosal vesicles. A, A preoperative photograph shows central and lateral distribution of vesicles with punctate areas of bleeding. B, Seven days after RF ablation. C, Normal remucosalization is evident 4 months after RF ablation. D, Normal-appearing tongue 8 months after RF ablation.

5 boys and 6 girls. Patient ages ranged from 4 to 16 years (mean age, 9.4 years). Eight patients had undergone previous procedures, including tracheotomy (n=1), laser therapy (n=3), subtotal excision (n=7), and sclerotherapy (n=4) (**Table**). Ten patients had experienced recurrent infections, and all had been treated with antibiotics (n=7) and/or chlorhexidine gluconate rinsing (n=5).

Radiofrequency ablation was performed by the senior author (R.R.) with the patients under general anesthesia and while using oral or nasal intubation, depending on the location of the LM. Intraoperative antibiotic and corticosteroid (dexamethasone, 0.5 mg/kg) treatment was administered. Radiofrequency ablation was performed using a coblator (EVac 70 Plasma Wand; ArthroCare Corp, Sunnyvale, Calif), and the vesicles and microcysts were removed in layers (from superficial to deep). The lesion's location determined the depth of the ablation. For lingual lesions, the vesicles were removed down to muscle and the wound was allowed to heal by secondary intention (**Figure 1** and **Figure 2**). Labial vesicles were ablated in a similar fashion to improve lip contour (**Figure 3**). Submucosal lesions that caused functional problems because of their size were partially excised (**Figure 4**). All patients were extubated at the end of the procedure and discharged home with 7 to 10 days of oral antibiotic therapy. Preoperative, intraoperative, and postoperative photographs of the lesions were obtained with a digital camera on the macro setting (Coolpix 5200; Nikon Inc, Melville, NY).

Parents were contacted and questioned about previous treatment, previous and current symptoms, postoperative recovery, and complications and were asked to compare the effectiveness of earlier treatments (excision, laser, or sclerotherapy) with that of RF ablation (**Figure 5**). To assess symptomatic control after RF ablation, parents were also asked to rate the degree of improvement of bleeding, infection, vesicle reformation, and pain, choosing between 5 possible answers.

RESULTS

Eleven patients underwent RF ablation with follow-up longer than 5 months (mean [range], 15.5 [5-28] months). Seven (64%) of the 11 patients tolerated oral intake in the recovery room; the remaining 4 patients (36%) began oral intake within 24 hours. No patient required postoperative endotracheal intubation. The estimated blood loss in all 11 patients was less than 5 mL each. All patients were admitted for observation and discharged the following day. Four patients (36%) resumed regular activities within a day; 5 (45%), within a week; and 2 (18%), within 2 weeks.

The parents of all 11 patients reported improvement in problems associated with LM (bleeding, infection,

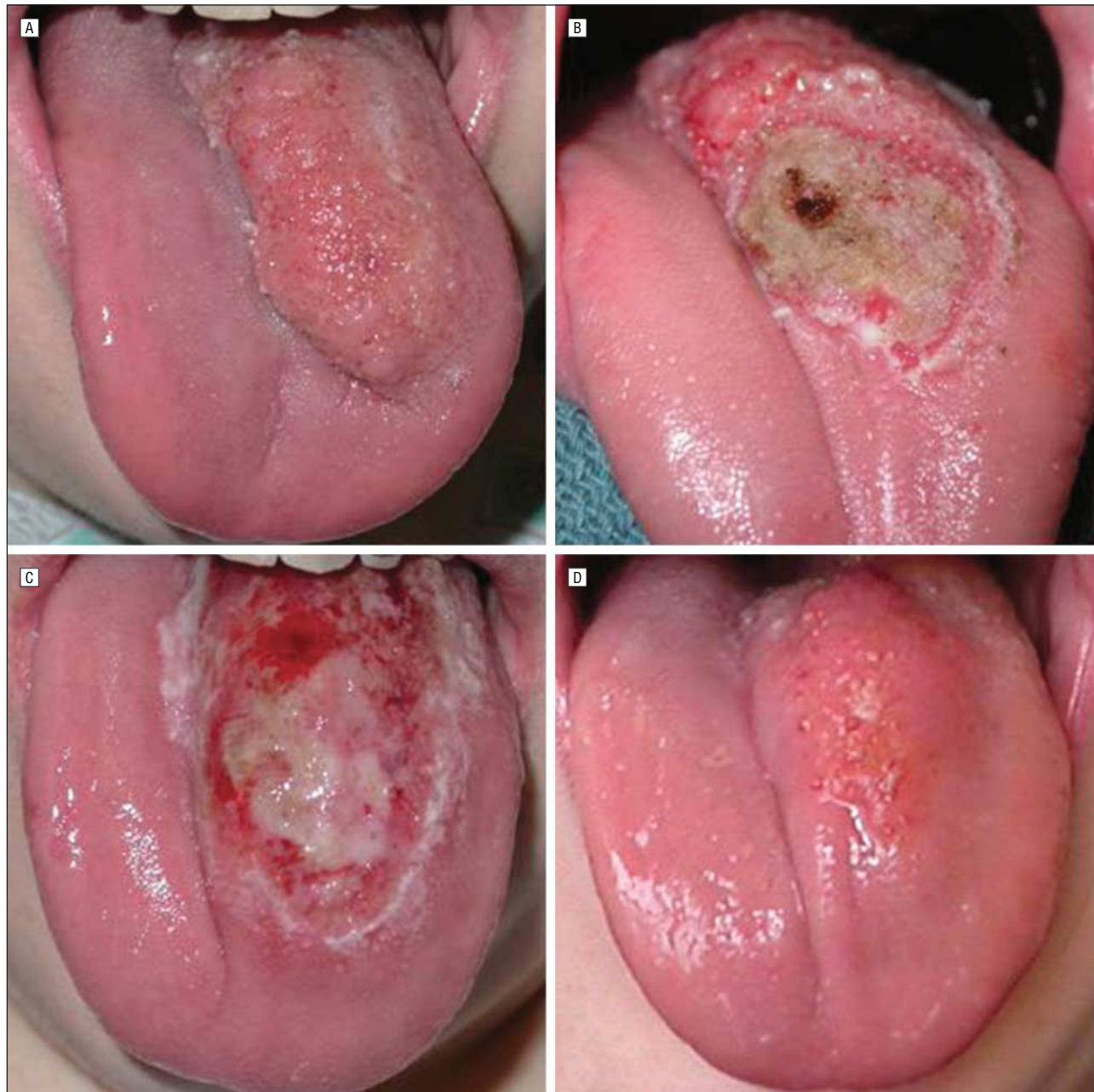


Figure 2. Microcystic lymphatic malformation of the tongue. A, Preoperative appearance. B, Intraoperative photograph shows the depth of the ablation. C, Postoperative image, obtained in the recovery room, shows minimal edema. D, Fewer mucosal vesicles are seen at the 6-month follow-up visit; however, increased fullness suggests submucosal recurrence.

vesicle formation, and pain) (Figure 5), as shown in the following tabulation:

| Degree of Improvement | No. (%) of Parents Reporting |
|---|------------------------------|
| Problems are worse now | 0 |
| No change in problems | 0 |
| Slight improvement of problems | 4 (36) |
| Significant improvement in the frequency and severity of problems | 6 (55) |
| All problems resolved | 1 (9) |

Of the 8 parents whose child had undergone previous procedures (excision, laser, or sclerotherapy), 5 (62%) reported that RF ablation was more effective at controlling symptoms. The remaining 3 parents (38%) reported that there was no difference compared with previous procedures.

Six (55%) of 11 patients had required intravenous or oral antibiotic therapy at least once a month before RF ablation. After RF ablation, no patient required monthly antibiotic therapy. One patient was given a course of intravenous antibiotic therapy (at 14 months after RF ablation) and subsequently underwent sclerotherapy; another patient required a single course of oral antibiotics (at 8 months after RF ablation).

COMMENT

Patients with microcystic LM of the oral cavity experience recurrent infections, swelling, and tenderness. In

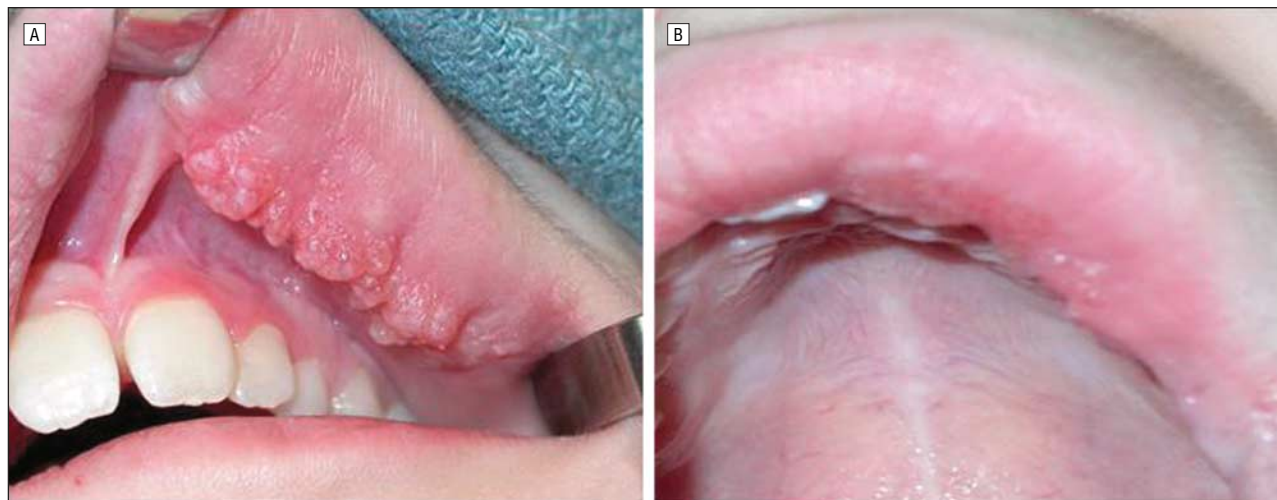


Figure 3. Microcystic lymphatic malformation of the left upper lip. A, Preoperative appearance. B, A photograph taken 3 months after radiofrequency ablation shows good lip contour and normal-appearing mucosa.

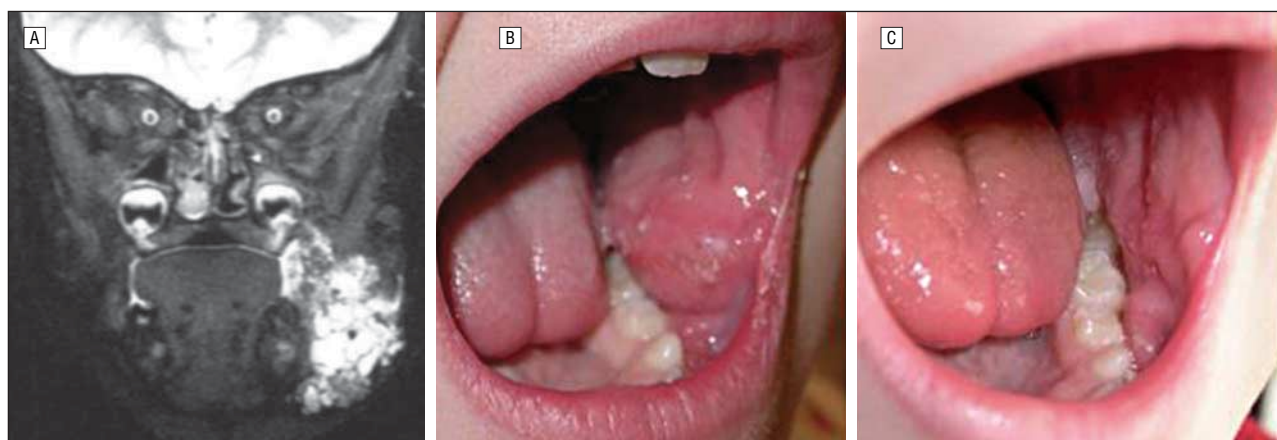


Figure 4. Microcystic lymphatic malformation (LM) of the left buccal space. This patient experienced pain and discomfort due to bite trauma. A, Preoperative T2-weighted magnetic resonance image of microcystic LM. The lesion extends laterally to the mandible. B, Preoperative appearance. C, Six months after partial resection with radiofrequency ablation, there is less protrusion into the occlusal plane.

addition, involvement of the tongue often causes dysphagia, dysarthria, or airway obstruction. Mucosal vesicles are often persistent and cause bleeding, tenderness, and oozing. Symptoms often worsen during upper respiratory tract infections or after trauma owing to intralesional bleeding. Treatment goals for microcystic LM include providing a safe airway, reducing symptoms, correcting functional problems, and improving appearance. Because complete resection is rarely possible, treatment focuses on reducing symptoms while causing as little damage as possible to adjacent tissue.

Patients in our study were typically treated with systemic antibiotics and attempts to improve oral hygiene, eg, with rinses and frequent dental care. Eight of these patients had undergone other procedures without resolution of the symptoms caused by vesicles. All of the patients reported an improvement in the frequency and severity of their symptoms, and more than half responded that there was significant improvement or complete reso-

lution. These findings are consistent with other published series on resection^{5,8} and sclerotherapy¹⁷⁻²⁰ in which success rates ranged from 0% to 50% for microcystic lesions. Published case reports and small series have also reported using in-column electrocoagulation,²¹ carbon dioxide laser excision,^{22,23} and RF ablation (with an electrode probe).²⁴

One deficiency of this study is that the questionnaire we used to assess symptom improvement has not been validated. An outcome survey that is specific to head and neck vascular anomalies in children would be an important instrument in monitoring symptoms and assessing the efficacy of various treatments.

In conclusion, our preliminary results for RF ablation of intraoral LM show minimal postoperative morbidity with minimal blood loss and early oral intake. All patients experienced at least some improvement of symptoms (vesicle formation, bleeding, infection, and pain), with more than half reporting a significant improvement or complete resolution. Further study is

1. What problems associated with LM did your child have prior to RF ablation?
2. What problems does your child have now?
3. Prior to RF ablation, how frequently did your child have problems?
 - (a) Several times a year
 - (b) Once a month
 - (c) >Once a month
 - (d) ≥Once a week
 - (e) Constant problems
4. After RF ablation, how frequently does your child have problems?
 - (a) Several times a year
 - (b) Once a month
 - (c) >Once a month
 - (d) ≥Once a week
 - (e) Constant problems
5. Prior to RF ablation, what kind of medical intervention did your child require? How frequently?
6. Since RF ablation, what kind of medical intervention does your child require? How frequently?
7. How well do you feel RF ablation has controlled your child's problems caused by LM? (Problems include bleeding, infection, vesicle formation, and pain.)
 - (a) Problems are worse now
 - (b) No change in problems
 - (c) Slight improvement of problems
 - (d) Significant improvement in the frequency and severity of problems
 - (e) All problems resolved
8. Prior to RF ablation, what other procedures has your child undergone to control problems of LM? Date(s)?
9. Compared with previous procedures, how would you rate RF ablation as a means of controlling your child's problems?
 - (a) Better than previous procedures
 - (b) No different than previous procedures
 - (c) Worse than previous procedures
10. How soon was your child able to tolerate oral intake after RF ablation?
 - (a) Immediately
 - (b) The following day
 - (c) Within a few days
 - (d) Within a week
 - (e) Longer than a week
11. How soon was your child able to return to regular activities after RF ablation?
 - (a) Immediately
 - (b) The following day
 - (c) Within a few days
 - (d) Within a week
 - (e) Longer than a week

Figure 5. Follow-up questionnaire administered during a telephone interview with the parents. LM indicates lymphatic malformation; RF, radiofrequency.

needed to determine the long-term efficacy of RF ablation of LM in the oral cavity.

Submitted for Publication: October 20, 2005; final revision received February 16, 2006; accepted March 27, 2006.

Correspondence: J. Fredrik Grimmer, MD, Division of Otolaryngology, Primary Children's Medical Center, 100 N Medical Dr, Suite 4500, Salt Lake City, UT 84113 (fred.grimmer@intermountainmail.org).

Author Contributions: Drs Grimmer, Mulliken, and Rahbar had full access to all the data in the study and take responsibility for the integrity of the data and the accuracy of the data analysis. *Study concept and design:* Grimmer. *Acquisition of data:* Grimmer and Rahbar. *Analysis and interpretation of data:* Grimmer, Mulliken, Burrows, and Rahbar. *Drafting of the manuscript:* Grimmer and Rahbar. *Critical revision of the manuscript for important intellectual content:* Grimmer, Mulliken, and Burrows. *Study supervision:* Rahbar.

Financial Disclosure: None reported.

Previous Presentation: This study was presented in part as a poster at the 20th annual meeting of the American Society of Pediatric Otolaryngology; May 28-30, 2005; Las Vegas, Nev.

REFERENCES

1. Groetach E. Hygroma coli cysticum and hygromae axillae. *Arch Surg.* 1938;36:394-479.
2. McClure C, Sylvester C. A comparative study of the lymphatico-venous communication in adult mammals. *Anat Rec.* 1909;3:353-354.
3. Burrows PE, Mason KP. Percutaneous treatment of low flow vascular malformations. *J Vasc Interv Radiol.* 2004;15:431-445.
4. Al-Salem AH. Lymphangiomas in infancy and childhood. *Saudi Med J.* 2004;25:466-469.
5. Padwa BL, Hayward PG, Ferraro NF, Mulliken JB. Cervicofacial lymphatic malformation: clinical course, surgical intervention, and pathogenesis of skeletal hypertrophy. *Plast Reconstr Surg.* 1995;95:951-960.
6. Giguere CM, Bauman NM, Smith RJ. New treatment options for lymphangioma in infants and children. *Ann Otol Rhinol Laryngol.* 2002;111:1066-1075.
7. Kennedy TL, Whitaker M, Pellitteri P, Wood WE. Cystic hygroma/lymphangioma: a rational approach to management. *Laryngoscope.* 2001;111:1929-1937.
8. Bloom DC, Perkins JA, Manning SC. Management of lymphatic malformations. *Curr Opin Otolaryngol Head Neck Surg.* 2004;12:500-504.
9. de Serres LM, Sie KC, Richardson MA. Lymphatic malformations of the head and neck: a proposal for staging. *Arch Otolaryngol Head Neck Surg.* 1995;121:577-582.
10. Powell NB, Riley RW, Guilleminault C. Radiofrequency tongue base reduction in sleep-disordered breathing: a pilot study. *Otolaryngol Head Neck Surg.* 1999;120:656-664.
11. Powell NB, Riley RW, Troell RJ, Li K, Blumen MB, Guilleminault C. Radiofrequency volumetric tissue reduction of the palate in subjects with sleep-disordered breathing. *Chest.* 1998;113:1163-1174.
12. Li KK, Powell NB, Riley RW, Troell RJ, Guilleminault C. Radiofrequency volumetric tissue reduction for treatment of turbinate hypertrophy: a pilot study. *Otolaryngol Head Neck Surg.* 1998;119:569-573.
13. Plant RL. Radiofrequency treatment of tonsillar hypertrophy [published correction appears in *Laryngoscope.* 2003;113:767]. *Laryngoscope.* 2002;112:20-22.
14. Temple RH, Timms MS. Paediatric coblation tonsillectomy. *Int J Pediatr Otorhinolaryngol.* 2001;61:195-198.
15. Nelson LM. Temperature-controlled radiofrequency tonsil reduction: extended follow-up. *Otolaryngol Head Neck Surg.* 2001;125:456-461.
16. Back L, Paloheimo M, Ylikoski J. Traditional tonsillectomy compared with bipolar radiofrequency thermal ablation tonsillectomy in adults: a pilot study. *Arch Otolaryngol Head Neck Surg.* 2001;127:1106-1112.
17. Yura J, Hashimoto T, Tsuruga N, Shibata K. Bleomycin treatment for cystic hygroma in children. *Nippon Geka Hokan.* 1977;46:607-614.
18. Herbreteau D, Riche MC, Enjolras O, et al. Percutaneous embolization with Ethibloc of lymphatic cystic malformations with a review of the experience in 70 patients. *Int Angiol.* 1993;12:34-39.
19. Ogita S, Tsuto T, Tokiwa K, Takahashi T. Intracystic injection of OK-432: a new sclerosing therapy for cystic hygroma in children. *Br J Surg.* 1987;74:690-691.
20. Mathur NN, Rana I, Bothra R, Dhawan R, Kathuria G, Pradhan T. Bleomycin sclerotherapy in congenital lymphatic and vascular malformations of head and neck. *Int J Pediatr Otorhinolaryngol.* 2005;69:75-80.
21. Vilalta A, Moreno-Arias GA, Mascaro JM. In-column electrocoagulation for lymphatic malformation of the tongue. *Br J Dermatol.* 2003;148:1279-1282.
22. April MM, Rebeiz EE, Friedman EM, Healy GB, Shapshay SM. Laser therapy for lymphatic malformations of the upper aerodigestive tract: an evolving experience. *Arch Otolaryngol Head Neck Surg.* 1992;118:205-208.
23. Chan J, Younes A, Koltai PJ. Occult supraglottic lymphatic malformation presenting as obstructive sleep apnea. *Int J Pediatr Otorhinolaryngol.* 2003;67:293-296.
24. Cable BB, Mair EA. Radiofrequency ablation of lymphangiomatous macroglossia. *Laryngoscope.* 2001;111:1859-1861.