

MITOMYCIN: EFFECTS ON LARYNGEAL AND TRACHEAL STENOSIS, BENEFITS, AND COMPLICATIONS

REZA RAHBAR, DMD, MD

STANLEY M. SHAPSHAY, MD

GERALD B. HEALY, MD

BOSTON, MASSACHUSETTS

The management of laryngeal and tracheal stenosis continues to challenge us, despite advances in surgical techniques and better understanding of the wound healing process. Injury to the airway mucosa is the inciting event, regardless of the cause of the stenosis. Mitomycin-C is an antineoplastic antibiotic that acts as an alkylating agent by inhibiting DNA and protein synthesis. It can inhibit cell division, protein synthesis, and fibroblast proliferation. Topical application of mitomycin-C (0.4 mg/mL) was used as an adjuvant treatment in the endoscopic laser management of laryngeal and tracheal stenosis in 15 patients. Fourteen patients (93%) have shown improvement of their airway and resolution of their preoperative symptoms. After a mean follow-up of 18 months, no complication was noted with regard to the application of mitomycin-C. This study gives promising findings on the efficacy and safety of mitomycin-C as an adjuvant treatment in the management of selected cases of laryngeal and tracheal stenosis.

KEY WORDS — endoscopic surgery, laryngeal stenosis, laser surgery, mitomycin-C, subglottic stenosis, tracheal stenosis.

INTRODUCTION

Treatment of laryngeal and tracheal stenosis remains one of the most difficult and perplexing problems in the area of head and neck surgery. Scar formation and restenosis remains the main cause of failure in the surgical management of airway stenosis. Modulation of the wound healing process to prevent excessive scar formation can play a major role in improving the success rate and decreasing the need for further surgery.

Mitomycin-C is an antiproliferative agent that can inhibit fibroblast proliferation and activity. It has been successfully used as an adjuvant treatment in a number of ophthalmologic procedures to decrease scar formation and restenosis.

A multicenter prospective clinical trial was undertaken in an effort to evaluate the efficacy and safety of the topical application of mitomycin-C in the prevention and treatment of airway stenosis. Mitomycin-C was used as an adjuvant treatment in the endoscopic laser management of laryngeal or tracheal stenosis in 15 patients. The preliminary results of some of these patients have been reported.¹

MATERIALS AND METHODS

Fifteen patients underwent endoscopic laser management of laryngeal or tracheal stenosis and the topical application of mitomycin-C at New England Med-

ical Center and The Children's Hospital, Boston, between January 1998 and December 1999. There were 8 male patients and 7 female patients. The patients' ages ranged from 2 to 78 years (mean, 32 years). The patients presented with preoperative symptoms of dyspnea interfering with routine daily activity, poor voice quality and vocal fatigue, and/or the inability to cap their tracheotomy tube. Included were 3 cases of glottic stenosis, 10 cases of subglottic stenosis, and 2 cases of tracheal stenosis (see Table).

Glottic Stenosis. One patient (No. 1) presented with a congenital anterior glottic web. Two patients (Nos. 2 and 3) were referred with posterior glottic stenosis and arytenoid fixation: 1 patient had undergone a tracheotomy and laryngofissure for repair of a blunt laryngeal trauma, and the other had undergone a tracheotomy and partial arytenoidectomy for bilateral vocal cord paralysis caused by a brain stem infarct. Only patient 3 was tracheotomy-dependent at the time of our evaluation, with an inability to cap the tracheotomy tube and poor voice quality.

Subglottic Stenosis. Three patients (Nos. 5, 11, and 13) presented with subglottic stenosis due to prolonged intubation because of cardiac surgery, pneumonia, and thalamic infarct, respectively. One patient (No. 4) presented with restenosis after a laryngotracheal reconstruction for a congenital subglottic stenosis (grade IV). No cause could be identified in

From the Department of Otolaryngology and Communication Disorders, The Children's Hospital (Rahbar, Healy), the Department of Otolaryngology and Laryngology, Harvard Medical School (Rahbar, Healy), the Department of Otolaryngology-Head and Neck Surgery, New England Medical Center (Shapshay), and Tufts University School of Medicine (Shapshay), Boston, Massachusetts.

Presented at the meeting of the American Laryngological Association, Orlando, Florida, May 13-14, 2000.

CORRESPONDENCE — Reza Rahbar, DMD, MD, Dept of Otolaryngology and Communication Disorders, The Children's Hospital, 300 Longwood Ave, Boston, MA 02115.

System

ect laryngoscopy
This glottiscope
or diagnosis and
and pathology



ts the false vocal
imal aperture that
hat dramatically

the spectrum of
rsal handle.
allows as well as

lae are contained



ion

ocraft1@aol.com

PATIENT DATA

Pt No.	Sex	Age (y)	Location of Stenosis	Etiology	Tracheotomy-Dependent	No. of Procedures	Initial Airway Stenosis	Thickness (mm)	Current Airway Stenosis	Initial Symptoms	Current Status	Follow-up (mo)
1	F	5	Glottic	Congenital web	No	2	60%	4	20%	B	F	12
2	M	14	Glottic	Laryngeal trauma	No	1	4-mm opening		7-mm opening	A, B	F	23
3	M	78	Glottic	Bilateral vocal cord paralysis	Yes	3	2-mm opening		5-mm opening	B, C	D, E	25
4	M	14	Subglottic*	Congenital	Yes	1	80%	4	20%	B, C	D, E	6
5	M	17	Subglottic	Prolonged intubation	No	1	80%	5	30%	A, B	F	13
6	F	33	Subglottic*	Idiopathic subglottic stenosis	No	1	80%	15	20%	A, B	F	25
7	F	38	Subglottic	Idiopathic subglottic stenosis	No	1	50%	12	20%	A, B	F	27
8	F	40	Subglottic*	Idiopathic subglottic stenosis	No	1	80%	4	20%	A, B	F	15
9	F	42	Subglottic*	Idiopathic subglottic stenosis	No	1	50%	7	10%	A, B	F	15
10	F	45	Subglottic*	Idiopathic subglottic stenosis	No	2	70%	10	10%	A, B	F	20
11	M	48	Subglottic	Prolonged intubation	Yes	2	95%	4	40%	A, B, C	D, E	19
12	M	53	Subglottic	Wegener's granulomatosis	No	1	50%	5	10%	A	F	15
13	M	56	Subglottic	Prolonged intubation	No	2	70%	5	30%	A, B	F	29
14	M	2	Tracheal	Prolonged intubation	No	1	70%	5	60%	Prolonged	Tracheotomy	15
15	F	5	Tracheal	Congenital stenosis	No	2	70%	3	10%	A, B	F	13

A — dyspnea on routine daily activity; B — poor voice quality and vocal fatigue; C — inability to cap tracheotomy tube; D — improved voice quality; E — ability to cap tracheotomy tube during day; F — resolution of preoperative symptoms.

*Circumferential scarring.

5 cases (patients 6 through 10), which were classified as idiopathic subglottic stenosis. Wegener's granulomatosis was the cause of subglottic stenosis in 1 patient (No. 12). Only 2 patients from this group (Nos. 4 and 11) were tracheotomy-dependent, with an inability to cap the tracheotomy tube and poor voice quality.

Tracheal Stenosis. One patient (No. 14), with a history of trisomy 21, presented with tracheal stenosis after prolonged intubation because of cardiac and pulmonary status. A second patient (No. 15) presented with tracheal stenosis after laryngotracheal reconstruction for a congenital subglottic and tracheal stenosis.

All patients underwent endoscopic examination and treatment under inhalational general anesthesia provided via a tracheotomy tube, when present, or intravenous anesthesia and Venturi jet ventilation. The airway size and length of stenosis were measured with an open tube ventilating bronchoscope or an endotracheal tube through a laryngoscope. Surgical exposure was obtained by placing the tip of a laryngoscope (Dedo, Healy-Jako, or anterior commissure scope) through the vocal cords for subglottic and tracheal stenosis. The laryngoscope was suspended from a Boston University suspension apparatus, and an operating microscope was used at 16x magnification for all cases. The CO₂ laser at a power setting of 4 to 6 W (time, 0.1 to 0.3 second), in a



superpulsed mode was used to make a tracheotomy or tracheal stenosis. The bronchoscope was used for the tracheal stenosis. The tracheal stenosis forces in a congenital stenosis within the trachea were used for the stenosis. Thereafter, a laryngoscope with mitomycin was used to the surgical stenosis. All patients were irrigated with 2% mitomycin after the procedure. Improvement in the stenosis was noted after the procedure.

A total of 22 patients (average, 5 patients each, 5 to 29 months) had 3 patients to 29 months of tube bronchoscopy.



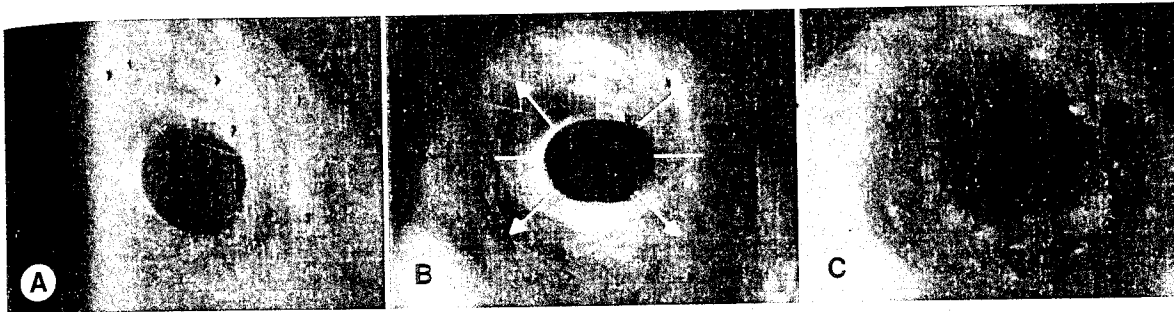


Fig 1. Subglottic stenosis. A) Preoperative. B) Radial laser incision. C) Postoperative.

superpulsed mode (0.25- to 0.3-mm spot size) was used to make radial incisions through the subglottic or tracheal stenosis (Fig 1). Ventilating open tube bronchoscopes were then used for dilation of the stenotic segment. The radial incisions in subglottic or tracheal stenotic areas served to guide the dilating forces in a controlled manner to preserve viable epithelium within the incision.² A similar laser setting was used for excision of glottic stenosis (Fig 2). Thereafter, a 10-mm cottonoid sponge was soaked with mitomycin-C 0.4 mg/mL and topically applied to the surgical site for 4 minutes. Then the area was irrigated with 20 to 30 mL of normal saline solution. All patients were observed for a minimum of 24 hours after the procedure. Success was defined as an improvement in the size of the airway and elimination of the preoperative symptoms.

RESULTS

A total of 22 procedures were performed in 15 patients (average, 1.5 procedures): 9 patients had 1 procedure each, 5 patients had 2 procedures each, and 1 patient had 3 procedures. The follow-up ranged from 6 to 29 months, with an average of 18 months. Open tube bronchoscopes and/or endotracheal tubes were

used for the measurement of the postoperative length and degree of stenosis under general anesthesia, or the measurements were made with fiberoptic laryngoscopy and still photographs taken by means of a 70° rigid telescope under topical anesthesia. Fourteen patients (93%) showed an improvement in the degree of airway stenosis and resolution of their preoperative symptoms (see Table). The postoperative length of the subglottic or tracheal stenosis could only be measured in patients who underwent general anesthesia because of the need for further surgery. There was no significant improvement noted in the length of the stenosis.

Glottic Stenosis. A total of 6 procedures were performed in 3 patients. Before operation, 1 patient demonstrated a 60% stenosis, and 2 patients had posterior or airway openings of 4 and 2 mm, respectively, compared to a postoperative stenosis of 20% and airway openings of 7 and 5 mm, respectively. Two patients are completely asymptomatic with regard to their preoperative symptoms. One patient was tracheotomy-dependent, was unable to cap the tracheotomy tube, and had poor voice quality. Currently, the tracheotomy tube is capped during the day without dyspnea on exertion, and the patient has good voice quality.

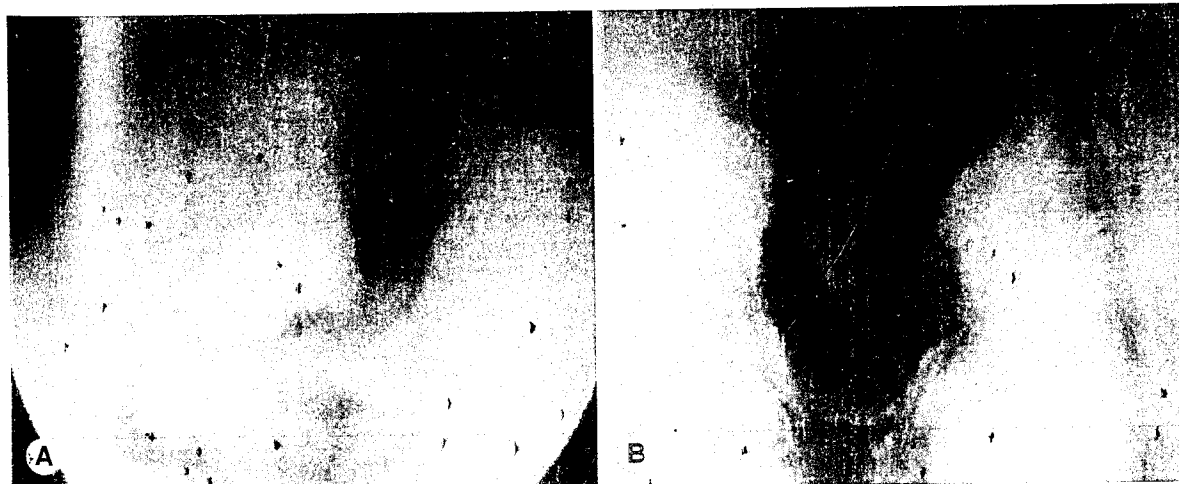


Fig 2. Posterior glottic stenosis. A) Preoperative. B) Postoperative.

ent Follow-up
us (mo)

12

23

25

6

13

25

27

15

15

20

19

15

29

ot- 15

13

-improved voice

examination
ul anesthesia
present, or
ventilation.
were mea-
choscope or
cope. Surgi-
the tip of a
terior 'com-
for subglot-
pe was sus-
nsion appa-
used at 16x
er at a pow-
econd), in a

The patient has not been decannulated because of his general medical condition following a brain stem infarct.

Subglottic Stenosis. A total of 13 procedures were performed in 10 patients. The preoperative stenosis ranged from 50% to 95% (mean, 71%), and the postoperative stenosis ranged from 10% to 40% (mean, 21%). The length of the stenosis ranged from 4 to 15 mm (average, 7 mm). Three patients had a length of stenosis equal to or greater than 1 cm. Before operation, 9 patients had moderate dyspnea with routine daily activity; currently, they are all free of symptoms. Two patients were tracheotomy-dependent before the procedure, with an inability to cap the tracheotomy tube and poor voice quality. Currently, both patients tolerate capping the tracheotomy tubes during the day and have improved voice quality. One patient (No. 11) has not been decannulated because of his general medical condition (diabetes and recurrent pneumonia); the second patient (No. 4) is scheduled for decannulation in the near future.

Tracheal Stenosis: A total of 3 procedures were performed in 2 patients. The preoperative degree of stenosis was 70% in both patients; the stenoses were 3 and 5 mm long, respectively. One patient (No. 15) is asymptomatic with 10% airway obstruction. The second patient (No. 14), whose history is significant for trisomy 21, tetralogy of Fallot, and pulmonary arteriovenous malformation, presented with restenosis and underwent tracheotomy because of worsening of his pulmonary and cardiac status.

DISCUSSION

The management of laryngeal and tracheal stenosis remains difficult, requiring accurate diagnosis and a proper treatment plan. The goal of any treatment is the restoration of an adequate airway, the provision of a competent larynx for protection against aspiration, and the achievement of a satisfactory voice. The first decision is whether an open surgical technique is necessary, or whether an endoscopic approach is adequate. Factors such as 1) age, 2) general medical condition, 3) cause, location, degree, length, and consistency of stenosis, and 4) previous treatment should be considered. There is still controversy with regard to the optimum approach in the treatment of laryngeal and tracheal stenosis.

Endoscopic management of laryngeal and tracheal lesions has undergone tremendous advancement in the past 2 decades. The development of microlaryngoscopy and adaptation of the binocular operating microscope, the introduction of endolaryngeal CO₂ laser surgery, the coupling of an endoscopic adapter to a ventilating bronchoscope, and the development

of the microspot manipulator allow microprecision and hemostatic ability, which were lacking with the standard instrumentation of conventional endoscopic techniques.³⁻⁶

Multiple endoscopic techniques have been described: microcauterization, dilation with local and systemic steroids, and cryosurgery have all had some success.^{7,8} Strong and Jako⁶ first published their experience with endoscopic CO₂ laser management of laryngeal stenosis in 1972. The CO₂ laser appears to be the most effective means for treating mild to moderate stenosis of the larynx and trachea endoscopically.⁹⁻¹²

With the advancements in endoscopic surgical technique and a better understanding of the wound healing process, and even with the introduction of mucosa-preserving laser surgery such as the microtrapdoor flap technique (Dedo and Sooy¹³) and radial incision and dilation (Shapshay et al²), there is still a high degree of scar formation and restenosis. A review of the literature reveals a wide range of success for endoscopic management of laryngeal and tracheal stenosis: Strong et al,¹⁴ 50% success; Andrews and Horowitz,¹⁵ 66% success; Simpson et al,¹⁶ 44% success; Carruth,¹⁷ 50% success; Shapshay and Simpson,⁵ 40% success; and Ossoff et al,¹⁸ 57% success. Although there are fundamental differences between these studies (definition of success; location, severity, and type of stenosis; length of follow-up), restenosis and scar formation remains the primary cause of failure.

Regardless of the surgical techniques, there is further injury to the airway mucosa that leads to fibroblast proliferation and collagen formation, which are the key to scar formation. Modulation of the wound healing response to prevent excessive scar formation can play a major role in increasing the success of surgical treatment and reducing the need for further surgery. In the past decade, the role of growth factors and fibrogenic peptides in the regulation and modulation of wound healing leading to fibrosis and scar formation has been reported.¹⁹⁻²¹ Pharmacological agents such as 5-fluorouracil and β -aminopropionitrile (β APN) have been shown to inhibit the development of collagen cross-linking, thus minimizing scar formation.^{22,23}

Kunitomo and Mori²⁴ presented the first clinical use of mitomycin-C in the prevention and treatment of scar formation in pterygium surgery. Later, Chen,²⁵ Palmer,²⁶ and Bergstrom et al²⁷ reported its use for prevention of restenosis in glaucoma surgery.

Mitomycin-C is an antibiotic produced by *Streptomyces caespitosus*. It is referred to as mitomycin-C

to differentiate both antineoplastic agents. Its antineoplastic agent inhibiting RNA also acts as a fibroblast ac-

mation. The exact effects of an antifibrotic agent may be direct or indirect. Evidence to suggest that activity may be gene-directed. Cells displaced by fibroblasts include condensation of nuclear fragments and an intact cell membrane. Khaw et al³ reported that mitomycin C prevents proliferation of fibroblasts. Mitomycin C prevents proliferation of fibroblasts. Mitomycin C prevents proliferation of fibroblasts.

Historical data with circumferential stenosis greater than 1 cm, pterygium, and loss of voice. We have shown that the characteristic of the trachea is the same as the characteristic of the larynx. The category of the stenosis is the same as the category of the stenosis. The experience of the stenosis is the same as the experience of the stenosis. The length of the stenosis is the same as the length of the stenosis. The endoscopic approach is the same as the endoscopic approach.

1. Rahbar et al. Intraoperative management of glottic and subglottic stenosis.

2. Shapshay et al. Endoscopic tracheal laser incision. *Ann Otol Rhinol Laryngol* 96:661-4.

3. Kleinsasser et al. Endoscopic tracheal laser incision. *Ann Otol Rhinol Laryngol* 96:661-4.

4. Polanyi et al.

to differentiate it from mitomycins A and B. It has both antineoplastic and antiproliferative properties. Its antineoplastic activity is similar to that of the alkylating agents, causing cross-linking of DNA and inhibiting RNA and protein synthesis. Mitomycin-C also acts as an antiproliferative agent that can inhibit fibroblast activity and suppress fibrosis and scar formation.

The exact mechanism by which mitomycin-C exerts an antifibroblast activity is unknown. There is evidence to suggest that the reduction of fibroblast activity may be mediated by apoptosis, which is a gene-directed process causing cell death. Apoptotic cells display a characteristic morphology that includes condensation of the nucleus and cytoplasm, nuclear fragmentation, and cytoplasmic blebbing with an intact cell membrane.²⁸ Lee et al²⁹ showed that mitomycin has antifibroblastic properties in vivo. Khaw et al³⁰ showed that in vitro, a single application of mitomycin could inhibit fibroblast proliferation. Mitomycin has been successfully used for prevention of stenosis in glaucoma surgery, dacryocystorhinostomy, optic nerve sheath fenestration, and pterygium recurrence.³¹⁻³⁵ The fibroblast population and collagen formation are substantially increased during the wound healing response that follows a mucosal insult such as a surgical procedure. The rationale of the use of mitomycin-C is to inhibit fibroblast proliferation during the postoperative phase without damaging the mucosal and epithelial growth.³⁶

Historically, endoscopic management of patients with circumferential scarring, a vertical scar greater than 1 cm, posterior scarring with arytenoid fixation, and loss of cartilaginous support had a high failure rate.¹⁶ We have presented 15 patients with laryngeal and tracheal stenosis. A group of these patients have characteristics of airway stenosis that falls into the category of high failure rate based on historical experience: 5 patients with circumferential stenosis of the subglottic area; 2 patients with posterior glottic stenosis and arytenoid fixation; and 3 patients with length of subglottic stenosis greater or equal to 1 cm. The endoscopic management of airway stenosis has

produced a success rate of 40% to 68%, as reported by experienced investigators, with most results being closer to 50%. We have defined success as clinical improvement of the degree of stenosis and the resolution of preoperative symptoms. We have shown improvement of the size of the airway and resolution of preoperative symptoms in 14 patients (93% success rate), without any complications, with a mean follow-up of 18 months. Three of our patients were tracheotomy-dependent at the time of our evaluation. They have shown improvement of their airway, allowing capping of their tracheotomy tube during the day, and improvement of their voice quality. Two of these patients have not been decannulated because of their general medical condition, and 1 is scheduled for decannulation in the near future.

Our results demonstrate that the topical application of mitomycin-C can be beneficial in the modulation of wound healing and in decreasing scar formation in the treatment of airway stenosis. Our study is the first to describe the use of mitomycin-C as an adjuvant treatment in the endoscopic management of laryngeal and tracheal stenosis in both pediatric and adult populations. Further research and randomized prospective clinical trials are needed to determine the most effective concentration and time of exposure of mitomycin-C, and the difference in efficacy and safety between single and multiple applications.

CONCLUSION

Treatment of laryngeal and tracheal stenosis remains a therapeutic challenge. Different surgical techniques have been proposed, and no single approach has proven satisfactory for all cases. With the advances in the surgical techniques and the recognition of the importance of mucosal preservation, the potential for endoscopic surgical techniques has expanded. Restenosis and scar formation remains the main cause of failure in these cases. This study reveals promising results in terms of the efficacy and safety of mitomycin-C as an adjuvant method for the management of laryngeal and tracheal stenosis.

REFERENCES

1. Rahbar R, Valdez TA, Shapshay SM. Preliminary results of intraoperative mitomycin C in the treatment and prevention of glottic and subglottic stenosis. *J Voice* 2000;14:282-6.
2. Shapshay SM, Beamis JF Jr, Hybels RL, Bohigian RK. Endoscopic treatment of subglottic and tracheal stenosis by radial laser incision and dilation. *Ann Otol Rhinol Laryngol* 1987;96:661-4.
3. Kleinsasser O. *Microlaryngoscopy and endolaryngeal microscopy*. Philadelphia, Pa: WB Saunders, 1968.
4. Polanyi TG, Bredemeier HC, Davis TW. A CO₂ laser for surgical research. *Med Biol Eng Comput* 1970;8:541-8.
5. Shapshay SM, Simpson GT. Lasers in bronchology. *Otolaryngol Clin North Am* 1983;16:879-86.
6. Strong MS, Jako GJ. Laser surgery in the larynx. Early clinical experience with continuous CO₂ laser. *Ann Otol Rhinol Laryngol* 1972;81:791-8.
7. Strome M. Cryosurgery: the effect on the canine endolaryngeal structures. *Laryngoscope* 1971;81:1057-65.
8. Friedman EM, Healy GB, McGill TJ. Carbon dioxide laser management of subglottic and tracheal stenosis. *Otolaryngol Clin North Am* 1983;16:879-86.

- ngol Clin North Am 1983;16:871-7.
9. Strong MS, Healy GB, Vaughan CW, Fried MP, Shapshay SM. Endoscopic management of laryngeal stenosis. *Otolaryngol Clin North Am* 1979;12:797-805.
 10. Healy GB. An experimental model for the endoscopic correction of subglottic stenosis with clinical applications. *Laryngoscope* 1982;92:1103-15.
 11. Shapshay SM, Beamis JF Jr, Dumon J-F. Total cervical tracheal stenosis: treatment by laser, dilation, and stenting. *Ann Otol Rhinol Laryngol* 1989;98:890-5.
 12. Strong MS, Jako GJ, Polanyi TG, Wallace RA. Laser surgery in the aerodigestive tract. *Am J Surg* 1973;126:529-33.
 13. Dedo HH, Sooy CD. Endoscopic laser repair of posterior glottic, subglottic, and tracheal stenosis by division or micro-trapdoor flap. *Laryngoscope* 1984;94:445-50.
 14. Strong MS, Vaughan CW, Polanyi G, Wallace R. Bronchoscopic carbon dioxide laser surgery. *Ann Otol Rhinol Laryngol* 1974;83:769-76.
 15. Andrews AA, Horowitz SL. Bronchoscopic CO₂ laser surgery. *Lasers Surg Med* 1980;1:35-9.
 16. Simpson GT, Strong MS, Healy GB, Shapshay SM, Vaughan CW. Predictive factors of success or failure in the endoscopic management of laryngeal and tracheal stenosis. *Ann Otol Rhinol Laryngol* 1982;91:384-8.
 17. Carruth AS. The role of lasers in otolaryngology. *World J Surg* 1983;7:719-22.
 18. Ossoff RH, Tucker GF, Duncavage JA, Toohill RJ. Efficacy of bronchoscopic carbon dioxide laser surgery for benign strictures of the trachea. *Laryngoscope* 1985;95:1220-3.
 19. Sera VR, Hall K, Low H, eds. Growth factors: from genes to clinical application. New York, NY: Raven Press, 1990.
 20. Border WA, Ruoslahti E. Transforming growth factor- β in disease: the dark side of tissue repair. *J Clin Invest* 1992;90:1-7.
 21. Crouch E. Pathobiology of pulmonary fibrosis. *Am J Physiol* 1990;259:159-84.
 22. Doolin EJ, Strande LF, Tsuno K, Santos MC. Pharmacologic inhibition of collagen in an experimental model of subglottic stenosis. *Ann Otol Rhinol Laryngol* 1998;107:275-9.
 23. Ingrams DR, Ashton P, Dhingra J, Shah R, Shapshay SM. Slow-release 5-fluorouracil and triamcinolone reduces subglottic stenosis in a rabbit model. *Ann Otol Rhinol Laryngol* 2000;109:422-4.
 24. Kunitomo N, Mori S. Studies on the pterygium. Part IV. A treatment of the pterygium by mitomycin-C instillation. *Acta Soc Ophthalmol Jpn* 1963;67:601-7.
 25. Chen C. Enhanced intraocular pressure controlling effectiveness of trabeculectomy by local application of mitomycin-C. *Trans Asia-Pacific Acad Ophthalmol* 1983;9:172-7.
 26. Palmer S. Mitomycin as adjunct chemotherapy with trabeculectomy. *Ophthalmology* 1991;98:317-21.
 27. Bergstrom TJ, Wilkinson WS, Skuta GL, Watnick RL, Elner VM. The effects of subconjunctival mitomycin-C on glaucoma filtration surgery in rabbits. *Arch Ophthalmol* 1991;109:1725-30.
 28. Desmulliere A, Redard M, Darby I, Gabbiani G. Apoptosis mediates the decrease in cellularity during the transition between granulation tissue and scar. *Am J Pathol* 1995;146:56-66.
 29. Lee DA, Lee TC, Cortes AE, Kitada S. Effects of mithramycin, mitomycin, daunorubicin, and bleomycin on human subconjunctival fibroblast attachment and proliferation. *Invest Ophthalmol Vis Sci* 1990;31:2136-44.
 30. Minaw FT, Doyle JW, Sherwood ME, Gilenson L, Schanz GS, McGorray S. Prolonged localized tissue effects from 5-minute exposures to fluorouracil and mitomycin C. *Arch Ophthalmol* 1993;111:263-7.
 31. Palmer SS. Mitomycin as adjunct chemotherapy with trabeculectomy. *Ophthalmology* 1991;98:317-21.
 32. Urban RC Jr, Kaufman LM. Mitomycin in the treatment of hypertrophic conjunctival scars after strabismus surgery. *J Pediatr Ophthalmol Strabismus* 1994;31:96-8.
 33. Kao SCS, Liao CL, Tseng JHS, Chen MS, Hsu PK. Dacryocystorhinostomy with intraoperative mitomycin. *Ophthalmology* 1997;104:86-91.
 34. Rubinfeld RS, Stein RM. Topical mitomycin-C for pterygia: is single application appropriate? *Ophthalmic Surg Lasers* 1997;28:662-9.
 35. Schipper I, Suppelt C, Gebbers J. Mitomycin-C reduces scar formation after excimer laser (193) photorefractive keratectomy in rabbits. *Eye* 1997;11:649-55.
 36. Lee DA. Antifibrosis agent in glaucoma surgery. *Invest Ophthalmol Vis Sci* 1994;35:3789-91.

LOCAL FOR E

Although recurrences, especially with glottic carcinoma. Their charts were reviewed or T1N0M0, 21 (more than 60%) of 161 patients classified versus stage II total laryngectomy had no curative treatment method of recurrent disease found after and inferior to the options are available.

KEY WORDS

For early glottic carcinoma rates have been reported for partial laryngectomy oncological results has emerged early glottic carcinoma 20 years.⁶⁻¹¹ open surgical treatment has been found to be postoperative after open partial laryngectomy. The perioperative complication rate is not disturbed frequently laryngectomy.^{13,15} As time-consuming and cost-effective procedure, both from the patient's perspective confirms that patients with early glottic carcinoma to UICC and recent survey.

From the Department of Otolaryngology, University of Michigan Medical Center, Ann Arbor, Michigan.
Presented at the meeting of the American Academy of Otolaryngology and Head and Neck Surgery, San Francisco, California, October 1998.
CORRESPONDENCE: Dr. Rahbar, Department of Otolaryngology, University of Michigan Medical Center, 1500 East Campus Drive, Ann Arbor, MI 48106-0610.