

Management of a Giant Lymphatic Malformation of the Tongue

Helena Rowley, MD; Antonio R. Perez-Atayde, MD; Patricia E. Burrows, MD; Reza Rahbar, DMD, MD

Lymphatic malformations can occur anywhere in the head and neck, and when they do so in the oral cavity, they can present a potential hazard to the airway. We describe a 4-year-old girl with a giant lymphatic malformation of the tongue and neck. This report illustrates the particular difficulties that may be encountered in cases involving giant lymphatic malformations of the cervicofacial region in the pediatric population. An overview of the etiology, diagnosis, histology, and options for the management of such lesions is outlined.

Arch Otolaryngol Head Neck Surg. 2002;128:190-194

Lymphatic malformations (LMs) of the cervicofacial region are caused by a defect in the embryological development of primordial lymphatic channels.¹ They present early and are either evident at birth or by the age of 2 years. Unlike hemangiomas, LMs do not involute over time. They occur throughout the body but are most common in the head and neck. Symptoms are related to the anatomical location of these lesions, as well as to the extent of involvement of the local anatomical structures. Lymphatic malformations can present with sudden enlargement as a result of either hemorrhage or inflammation. Giant cervicofacial LMs can be life-threatening, especially if they encroach on the airway.^{2,3}

REPORT OF A CASE

A 4-year-old girl was referred for evaluation of an LM of the tongue and neck that she had had since birth. She had a complicated medical history, which was sig-

nificant for resection of the LM of the floor of the mouth at 2 weeks after birth and for excision of the LM of the neck at the age of 6 months.

At the age of 4 years, she was referred to the Vascular Anomaly Clinic at Children's Hospital, Boston, Mass, where she was noted to have a giant swelling of the tongue, causing her tongue to protrude approximately 12 cm outside the oral cavity (**Figure 1**). A diagnosis of LM was made after clinical examination and imaging (**Figure 2**).

Initial treatment involved injection of the neck and base of tongue with OK-432 and the lingual microcystic LM with ethanol. After sclerotherapy, steroids and antibiotics were prescribed, and the patient was carefully followed up to observe for resolution. The injections were repeated 6 weeks later using OK-432 in both the macrocystic and microcystic parts of the lesion. There was some decrease in the thickness of the tongue, but overall, its size changed minimally. Because the protrusion of the tongue had not resolved and the patient was experiencing increasing difficulty with speech and eating, a decision was made to proceed with resection of the lingual LM.

From the Departments of Otolaryngology and Communication Disorders (Drs Rowley and Rahbar), Pathology (Dr Perez-Atayde), and Radiology (Dr Burrows), Children's Hospital, and the Department of Otolaryngology and Laryngology, Harvard Medical School (Drs Rowley and Rahbar), Boston, Mass.

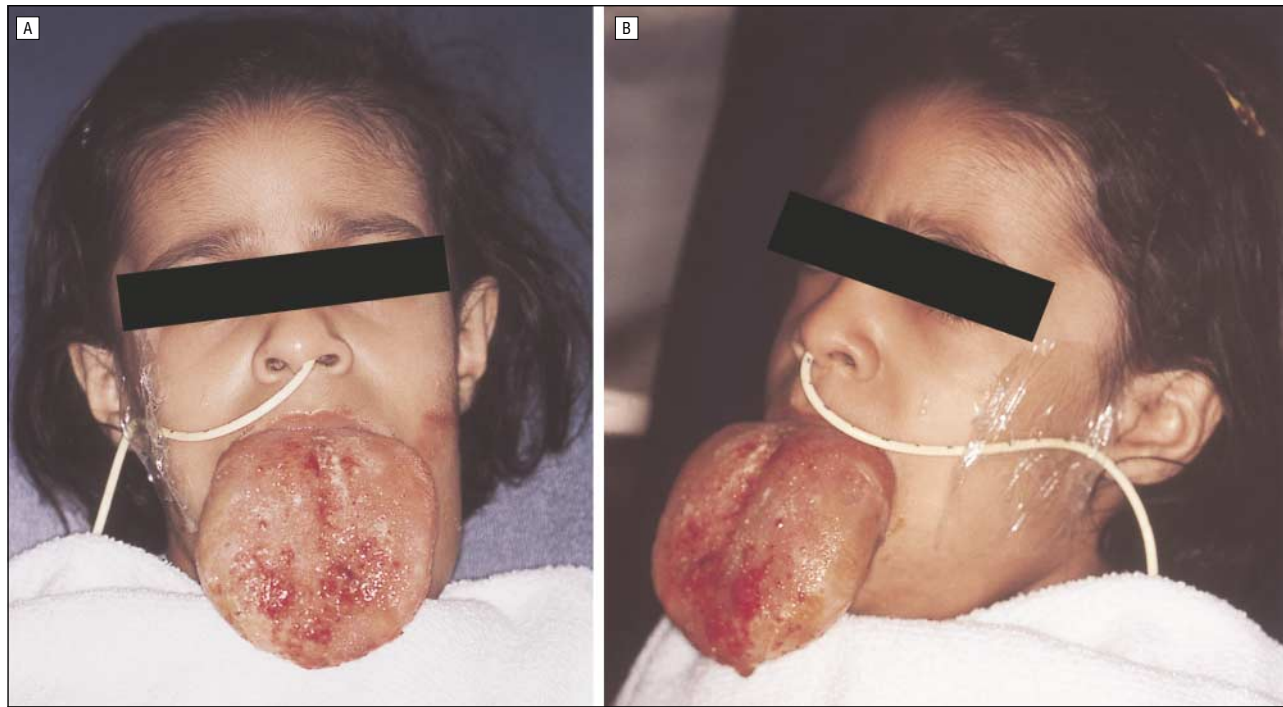


Figure 1. Patient at initial presentation. A, Frontal view. B, Lateral view.

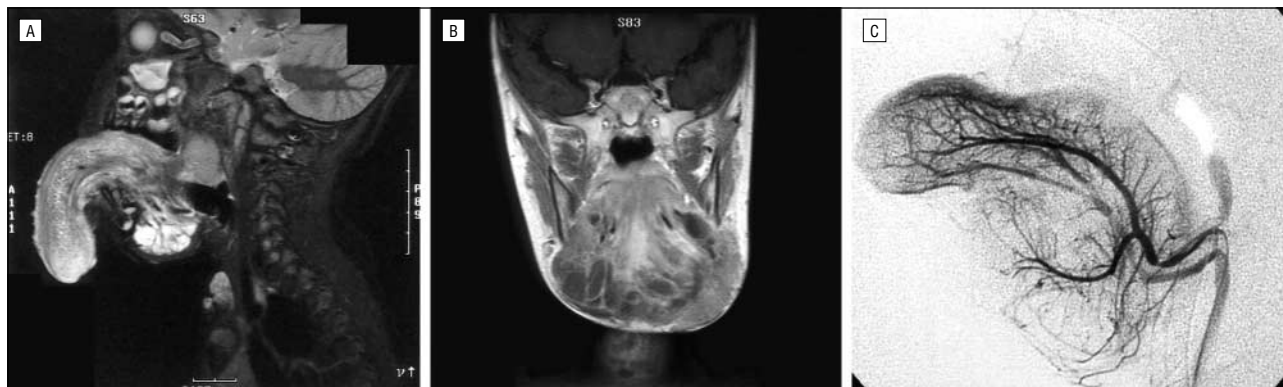

Figure 2. A, Sagittal magnetic resonance imaging scan. B, Coronal magnetic resonance imaging scan. C, Angiogram.

During surgery, direct laryngoscopy revealed a normal hypopharynx and glottis. The LM involved a large portion of the anterior two thirds of the tongue; however, there was minimal involvement of the tongue base. The patient underwent resection of the LM, which involved a hemiglossectomy, as well as removal of mid-portion of the tongue (**Figure 3**). The lesion was excised and sent for histological analysis. The patient was intubated for 24 hours, after which she was then extubated without difficulty. She was observed in the hospital for 5 days. Histological examination of the sections of the tongue mass revealed an LM involving the entire specimen, from the squamous mucosa, which appeared hy-

perplastic and thickened, to the submucosa and deep muscular tissue (**Figure 4**). Numerous, irregular, thin-walled vascular channels lined by flat endothelium were observed throughout, and their lumens were either empty or contained lymph. Dense clusters of lymphocytes were present within the connective tissue between the channels.

The patient has received follow-up care at the Vascular Anomaly Clinic and the Department of Otolaryngology. She has resumed an oral diet and has appropriate speech for her age, and there has been no recurrence of the LM during a 2-year follow-up (**Figure 5**). There are plans for excision of the neck malformation in approximately 6 months.

COMMENT

Lymphatic malformations typically present in the first year of life, usually as a compressible mass in the neck, mouth, tongue, larynx, or parotid region. Two thirds of LMs are present at birth, and more than 90% are clinically obvious by the age of 2 years. Depending on their location, large LMs of the head and neck can cause significant airway compromise either at birth or in the young infant, and urgent airway intervention in the form of either intubation or tracheotomy may be required.

Lymphatic malformations can be characterized as macrocystic, microcystic, or combined. The old

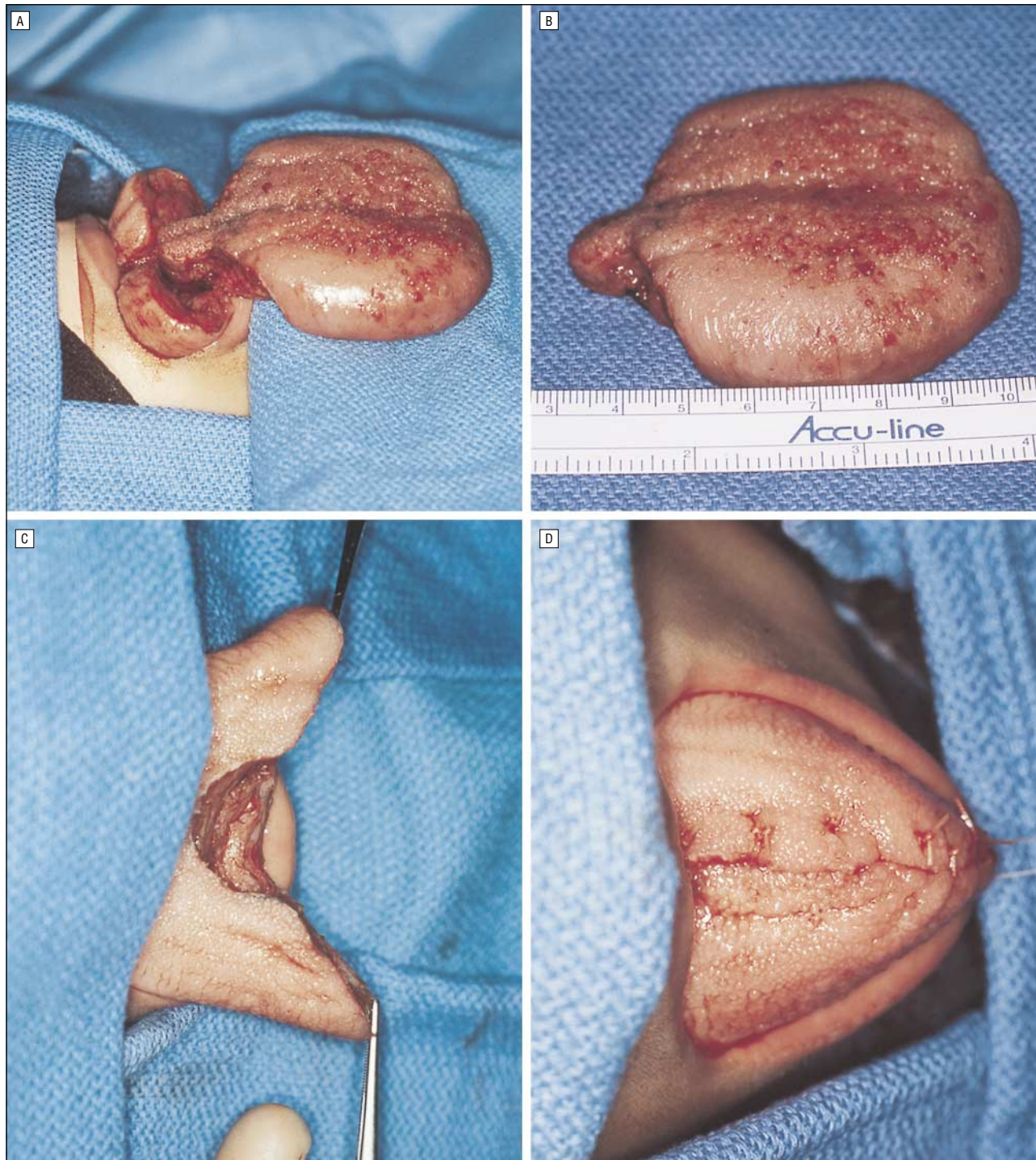


Figure 3. Intraoperative pictures taken during hemiglossectomy. A, Hemiglossectomy. B, Specimen (top of ruler in centimeters). C and D, Reconstructed tongue.

terms for these types are *lymphangioma* for microcystic LMs and *cystic hygroma* for macrocystic LMs. Macrocystic lesions typically consist of large, thick-walled cysts and commonly occur in the neck. Microcystic LMs are made up of multiple smaller cysts and are frequently found in the oral cavity and oropharynx.

Lymphatic malformations can present in various sites, and the clinical presentation may differ accordingly; for instance, lymphatic infiltration of the tongue results in macroglossia, which may impair speech and eating or may be complicated by swelling or bleeding. Lymphatic malformations of the neck may occur in the anterior or posterior tri-

angles, and typically the patient presents with a diffuse compressible swelling of the neck, which may or may not be tender and may or may not be rapidly enlarging, depending on whether there has been recent inflammation or hemorrhage. Lymphatic malformations of the larynx may present with stridor and airway compromise.

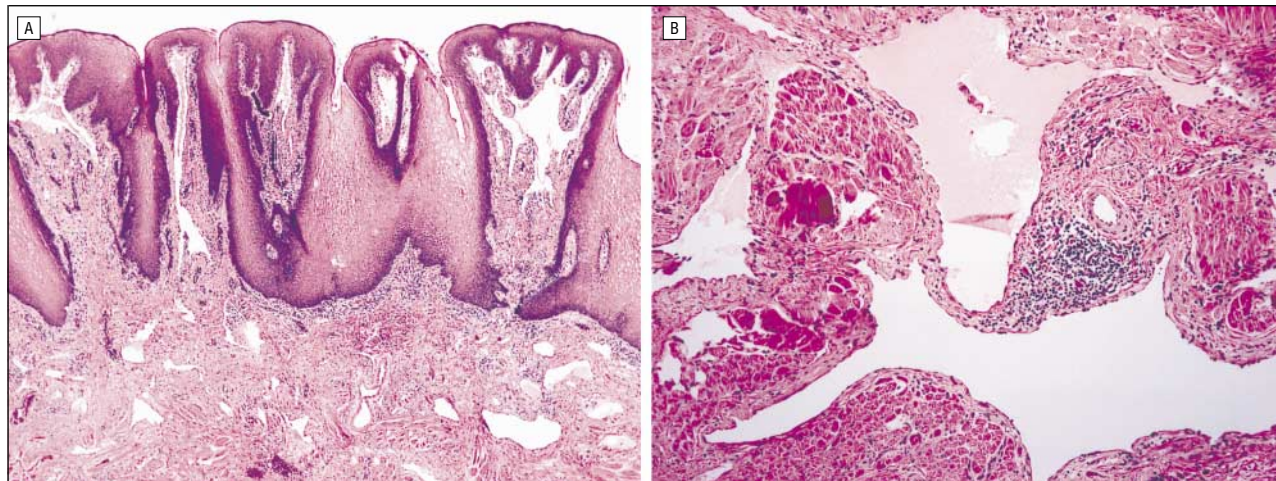


Figure 4. Lymphatic malformation (hematoxylin-eosin, original magnification $\times 40$ [A] and $\times 80$ [B]).

Diagnosis is relatively straightforward, and modern imaging contributes greatly to accurate diagnosis. Although ultrasonography, computed tomography, and magnetic resonance imaging play a role in outlining the cystic appearance of the lesion, magnetic resonance imaging is the imaging modality of choice.³ All LMs are hyperintense on T2-weighted sequences owing to their high water content. Contrast administration usually results in enhancement of the rims of large cysts or septae.

Two major complications caused by LMs are intralesional bleeding and infection. Bleeding could be spontaneous or due to trauma. Viral or bacterial infection can also cause enlargement of LMs. In the cervicofacial region, enlargement of the LM could lead to upper airway obstruction, dysphagia, and cosmetic deformity.

There are 2 main treatment options: intralesional embolization with OK-432^{4,5} or surgical excision.^{2,6,7} OK-432 is a lyophilized incubation mixture of group A streptococci and *Streptococcus pyogenes*. It produces an inflammatory reaction, followed by gradual regression of the lesion. The use of OK-432 is considerably more effective if the lesion is macrocystic.^{5,6,8} In cases involving microcystic lesions or those in which the use of OK-432 has failed to produce an impressive result, surgical resection should be considered. In the case reported herein, OK-432 injections were effective in shrinking the macrocysts

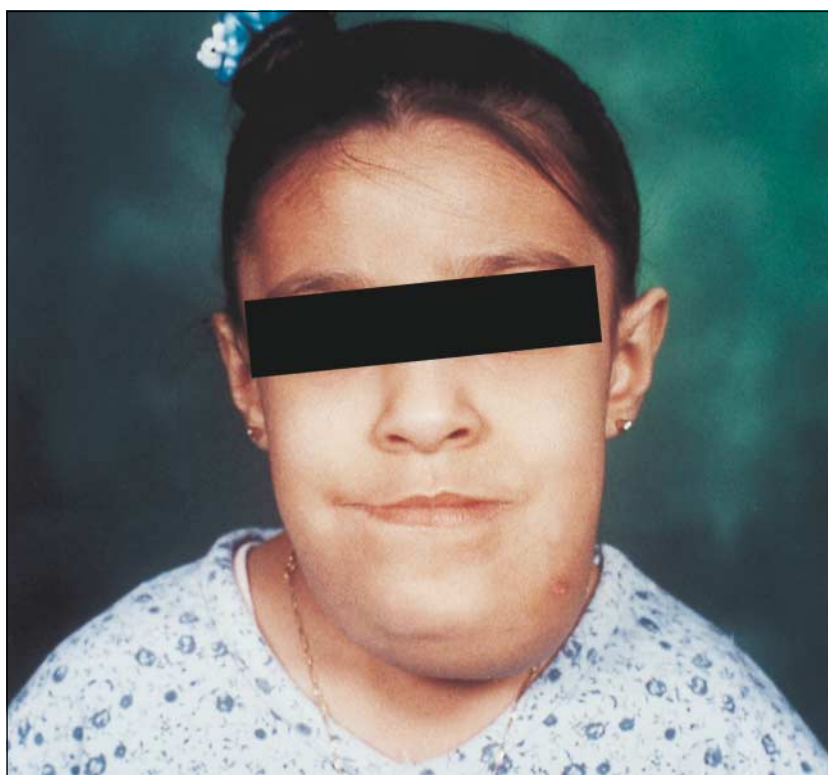

Figure 5. Patient at 6 months after surgery.

in the base of the tongue. This reduced the lingual protrusion, thus minimizing the amount of tongue that needed to be resected to achieve oral closure.

A number of issues should be considered when planning surgical resection of an LM. First, the timing of surgery is important, as is the mode of dissection, whether by sharp dissection or laser. It is also important to consider whether it is best to attempt complete resection in 1 procedure or whether staged resection is

necessary. To address these issues in our practice, we have found that subdividing LMs into subtypes is useful. We divide LMs into 2 types. Type I LMs are located below the level of the mylohyoid muscle. In general, these LMs may be safely resected within the first 12 months of life; sharp dissection is frequently the modality of choice; and they can frequently be resected during 1 procedure. Type II LM is found above the level of the mylohyoid muscle and is frequently poorly defined; therefore,

the planes between the malformation itself and the normal anatomy may be difficult to dissect. Complete surgical resection in these circumstances can be quite a challenge. The use of loupes or the operating microscope is helpful, and a nerve stimulator is imperative, as normal anatomy is frequently disrupted. We believe that laser dissection has a particular role in sites where disease is not readily resectable by sharp dissection, eg, lesions of the larynx, oropharynx, and oral cavity. These lesions are particularly suitable for use of the carbon dioxide or Nd:YAG laser. For type II LMs, we recommend that surgery be carried out before the age of 5 years if possible, and factors such as blood loss, duration of procedure, and extent of dissection may help to determine whether multiple procedures are needed.

Resection is the only way to potentially "cure" an LM. The surgeon must consider possible involvement

of neural and vascular structures and try to limit blood loss, with preservation of all vital structures.^{3,9} Traditionally, giant lesions have been removed in staged resections; however, cases such as the one reported herein serve to demonstrate that complete surgical resection in 1 sitting is possible and desirable, provided preset goals regarding blood loss and duration of procedure can be adhered to.

Accepted for publication August 27, 2001.

Corresponding author and reprints: Reza Rahbar, DMD, MD, Department of Otolaryngology and Communication Disorders, Children's Hospital, 300 Longwood Ave, Boston, MA 02115 (e-mail: reza.rahbar@tch.harvard.edu).

REFERENCES

1. Zadvinskis DP, Benson MT, Kerr HH, et al. Congenital malformations of the cervicothoracic

lymphatic system: embryology and pathogenesis. *Radiographics*. 1992;12:1175-1189.

2. Padwa BL, Hayward PG, Ferraro NF, Mulliken JB. Cervicofacial lymphatic malformation: clinical course, surgical intervention, and pathogenesis of skeletal hypertrophy. *Plast Reconstr Surg*. 1995;95:951-960.
3. Lille ST, Rand RP, Tapper D, Gruss JS. The surgical management of giant cervicofacial lymphatic malformations. *J Pediatr Surg*. 1996;31:1648-1650.
4. Mulliken JB, Fishman SJ, Burrows PE. Vascular anomalies. *Curr Probl Surg*. 2000;37:517-584.
5. Greinwald JH Jr, Burke DK, Sato Y, et al. Treatment of lymphangiomas in children: an update of Picibanil (OK-432) sclerotherapy. *Otolaryngol Head Neck Surg*. 1999;121:381-387.
6. Brewis C, Pracy JP, Albert DM. Treatment of lymphangiomas of the head and neck in children by intra-lesional OK-432 (Picibanil). *Clin Otolaryngol*. 2000;25:130-134.
7. Fageeh N, Manoukian J, Tewfik T, Scloss M, Williams HB, Gaskin D. Management of head and neck lymphatic malformations in children. *J Otol*. 1997;26:253-258.
8. Luzzatto C, Midrio P, Tchaprassian Z, Guglielmi M. Sclerosing treatment of lymphangiomas with OK-432. *Arch Dis Child*. 2000;82:316-318.
9. DeLuca L, Guyuron B, Najem RW. Management of an extensive cervicofacial lymphovenous malformation of the maxillofacial region. *Ann Plast Surg*. 1996;36:951-960.