

## FAT IMPLANTATION INTO REINKE'S SPACE: A HISTOLOGIC AND STROBOSCOPIC STUDY IN THE CANINE

PEAK WOO, MD

NEW YORK, NEW YORK

REZA RAHBAR, MD, DMD

BOSTON, MASSACHUSETTS

ZHI WANG, MD

BOSTON, MASSACHUSETTS

The scarred vocal fold is a cause of persistent dysphonia after laryngeal trauma, microsurgery, and tumor resection. The loss of Reinke's space with scar and stiffness is the primary cause. This study explores the technical aspects of endoscopic implantation of fat as an autologous implant for restoring the bulk and pliability of the vocal folds. Fat from the buccal area was harvested and prepared in 6 dogs. A mucosal flap submucosal pocket was prepared by means of microlaryngoscopy instrumentation. The fat implant was placed into the submucosal pocket. The mucosal flap was sutured endoscopically. Six weeks later, the larynx was harvested and mounted, and vocal fold oscillation was studied while driven by a humidified flow source. The vibratory patterns were studied by stroboscopy. Histologic sections of the vocal folds were made in the coronal plane. All 6 specimens had histologic evidence of viable implanted fat and/or fibrous tissue at the implant site. The site of implantation was in the superior aspect of the vocal fold, but contributed to mass in vocal fold bulk. This increase in bulk histologically corresponded to stroboscopic evidence of increased mass. On stroboscopy, the implant side continued to demonstrate good vibratory function. The study shows that fat implantation can be carried out as an endoscopic procedure. Fat implantation may be useful as a surgical procedure for restoration of Reinke's space. It may be applicable in patients with scars, sulcus vocalis, or vocal fold atrophy.

KEY WORDS — dysphonia, fat implantation, Reinke's space, scarred vocal fold, stroboscopy.

### INTRODUCTION

The vibratory function of pliable vocal folds is important in the production of a clear sound. Structural abnormalities remaining after microlaryngeal surgery, trauma, and tumor resection often contribute to residual dysphonia. Scarring and fibrosis of the vocal folds are the principal causes of postoperative dysphonia.<sup>1</sup> The body-cover theory of vocal cord vibration has been demonstrated in histologic detail by Hirano and Kakita.<sup>2</sup> Histologic examination of the human vocal folds has demonstrated the unique layered structure of the vocal fold cover. When scar and vocal fold stiffness is the cause of persistent dysphonia, the resultant vocal fold oscillation demonstrates loss of mucosal amplitude and wave secondary to disruption or loss of Reinke's space. The operative options in patients with scarred vocal folds are limited. The use of collagen injection for glottal incompetencies has been advocated by Ford.<sup>3</sup> Recently, there has been interest in the use of fat as an injectable material in the augmentation of the vocal folds. This has been used in patients with glottal incompetencies due to vocal fold paralysis, as well as other causes.<sup>4,5</sup> Fat injection into the vocalis muscle, as augmentation

material, does not answer the quest for a more pliable material to substitute for the superficial layer of the lamina propria in the vocal fold. Injection of fat into a scar is often difficult to perform. Some data suggest that the resorption rate of fat injected into the vocal fold is high.<sup>6</sup> Although the success of fat as a permanent injectable augmentation alternative to Teflon has not been fully demonstrated, fat has many advantages. The viscoelastic properties of fat are close to those of the superficial layer of the lamina propria. Fat is softer than Teflon, collagen, or Gelfoam. It is readily available as an autologous tissue. Experience with fat over time has been well researched.<sup>7</sup> The use of fat as an implant rather than in the injected form has theoretical and practical advantages. Fat implantation is the placement of fat into a surgically created pocket. By dissection of a pocket to receive the fat implant, the fat may be placed into the defect in a precisely measured amount.

Fat implantation into the vocal folds has been studied in animal models by previous authors. In 1989, Wexler et al<sup>8</sup> studied the fate of fat in a canine scarring model. They showed conclusively that the scarred canine larynx may be rehabilitated by thy-

From the Department of Otolaryngology-Head and Neck Surgery, Tufts University School of Medicine and New England Medical Center, Boston, Massachusetts. This study was performed in accordance with the PHS Policy on Humane Care and Use of Laboratory Animals, the NIH *Guide for the Care and Use of Laboratory Animals*, and the Animal Welfare Act (7 U.S.C. et seq.); the animal use protocol was approved by the Institutional Animal Care and Use Committee (IACUC) of New England Medical Center.

Presented at the meeting of the American Broncho-Esophagological Association, Orlando, Florida, May 6-7, 1996.

CORRESPONDENCE — Peak Woo, MD, Dept of Otolaryngology-Head and Neck Surgery, Mount Sinai Medical Center, Box 1191, 5 E 92nd St, New York, NY 10029.

rotomy, submucosal fat implantation into Reinke's layer, and suture closure of the wound. The fat implant survived and restored vocal fold vibration. Histologic examination showed viable fat in Reinke's space. In another study, the same group showed the vibratory capabilities of the fat-implanted vocal fold to be superior to those of the scarred vocal fold model.<sup>9</sup> Their surgical approach, however, requires open thyrotomy and tracheostomy. The possibility of improved vocal function with fat implantation propelled the search for a better surgical alternative for performing fat implantation than open thyrotomy and tracheostomy. One possibility is endoscopic fat implantation. With improved instrumentation and endoscopic suturing techniques, endoscopic fat implantation may be possible. It would retain the advantages of fat implantation without the need for tracheostomy or laryngofissure. The purpose of this study was to explore the limits of an endoscopic approach to fat implantation in the vocal fold in a canine model. In addition, the fate of the fat implant and the effect of the fat implant on the vibratory function were tested after surgery by stroboscopy and histologic examination.

#### MATERIAL AND METHODS

**Animal Surgery.** Six adult conditioned laboratory dogs were used for this study. The body weights ranged from 14 to 20 kg. All animal surgery and care procedures were carried out in accordance with institutional policies on care of animals. In each experiment, the left vocal fold served as the control side, and the right side served as the experimental side. The animals were anesthetized with Nembutal and maintained under a state of anesthesia with spontaneous ventilation by periodic intravenous maintenance of Nembutal. A buccal fat pad measuring 3 × 10 × 5 mm was harvested through a buccal incision. The fat donor site was closed with a 3-0 chromic suture. The fat pad was preserved in saline gauze for later implantation. The adult Jako laryngoscope (Pilling, Ft Washington, Pa) was placed into position, and suspension microlaryngoscopy was carried out. With standard microlaryngeal instrumentation and operative magnification, the endoscopic procedure to create a pocket for fat implantation commenced. A submucosal pocket was created by making a 1-cm incision on the superior surface of the right true vocal fold. The incision was expanded by blunt and sharp dissection to create a submucosal pocket along the medial edge of the vocal fold. With a cup forceps, the mucosal flap was retracted medially. The microdissector and microscissors were used to create a pocket medially and inferiorly along the contour of the vocal fold. Care was taken to stay in the submucosal plane and avoid

vocal ligament injury. Once the submucosal pocket had been created, adrenaline-soaked (1:1,000) cotton pads were placed into the pocket to achieve hemostasis. The autogenous fat was shaped into a 6 × 4 × 2-mm implant and fashioned to fit into the submucosal pocket. The fat was placed into the submucosal pocket with cup forceps. The mucosal flap was placed into position. To prevent fat dehiscence from the incision and to obtain complete edge-to-edge approximation of the mucosal edge, one 4-0 chromic suture was placed endoscopically to suture the edges of the vocal folds.<sup>10</sup>

**Endoscopic Evaluation and Excised Larynx Preparation.** The animals were examined at 6 weeks after endoscopic surgery under general anesthesia. The larynx was harvested after euthanasia. Excess soft tissue was trimmed from the larynx, and the larynx was mounted in a Plexiglas larynx holder. The vocal folds were approximated by a suture across the vocal process. The excised larynx phonation model is fashioned after Baer.<sup>11</sup> The laryngeal holder has pressure taps for subglottic pressure, flow metering, and adjustment of flow. A heated, humidified airflow source (Bird heater humidifier controller) was used to drive the vocal folds. The air temperature was set at 36°C at 100% humidification. The subglottic pressure necessary to initiate the onset of steady vocal fold oscillation was recorded. During sustained vocal fold oscillation, a stroboscopic light source and video camera were used to record vocal fold vibratory behavior (Power Instrumentation, Skokie, Ill). Stroboscopic endoscopy examination was used to compare the vibratory behavior of the control side with that of the experimental side as to vibratory capability, amplitude, mass, and mucosal wave.

**Histology.** After the studies of vibratory behavior were completed, the larynx was fixed in 10% formalin, dehydrated, and processed for histology. The larynx was mounted and cut in the coronal plane. Sections were made in 10- $\mu$ m increments. Histologic sections were obtained at the same level for both the control (left) and experimental (right) vocal folds through the membranous vocal folds. The slides were stained by hematoxylin and eosin. The laryngeal sections were examined. Comparison was made between the experimental side and the control side for 1) evidence of the fat implant, 2) the existence of inflammation, and 3) the thickness of the submucosal layer. Qualitative histologic changes in Reinke's space were recorded.

#### RESULTS

**Operative and Postoperative Findings.** All the animals tolerated the procedure without difficulty. The operation lasted from 30 to 60 minutes. The

SUMMARY OF SUBGLOTTIC PRESSURE AND FLOW RATE AT THRESHOLD OF PERIODIC VOCAL FOLD OSCILLATION

Specimen	Subglottic Pressure (cm H <sub>2</sub> O)	Flow Rate (mL/s)	Vibration of Vocal Fold
1	8	240	Yes
2	12	300	Yes
3	10	310	Yes
4	10	220	Yes
5	9	250	Yes
6	14	350	Partial decrease

wide-bore operating laryngoscope gave good binocular vision for creating the mucosal flap. Although the superior aspect of the submucosal pocket was easy to create, operating on the undersurface of the vocal fold was more arduous and required blunt probes and dissectors. A submucosal pocket was, however, made in each experiment without difficulty. The fat implant could be placed easily into the submucosal pocket to add bulk to the vocal fold. After the fat was implanted, there was a visible bulge of the vocal folds medially. A suture was necessary to keep the fat from herniating through the incision. The endoscopically placed sutures were positioned on the superior surface of the vocal folds. Bleeding was minimal. The dissection in the submucosal plane was able to be used to create submucosal pockets of various sizes. In all the specimens, Reinke's space was easily found. Endoscopic fat implantation could be performed with existing microinstruments.

The postoperative courses were uncomplicated. None of the animals had difficulty with the airway or deglutition. All the animals were noted to have voice after the procedure. Because of the technical difficulty of recording voice in the animal shelter, only qualitative impressions of the voice could be taken.

There was minimal voice change compared to the preoperative state after the first week.

**Videostroboscopy Findings.** Videostroboscopy recordings were generated from the excised canine preparation. Stable vibration was seen in all the specimens. The subglottic pressure threshold necessary for stable oscillation ranged from 8 to 14 cm H<sub>2</sub>O (see Table). Prior experience (unpublished data) using the same experimental setup in normal canine larynges showed thresholds of oscillation at 5 to 10 cm H<sub>2</sub>O. The induced vocal fold vibration showed a vibratory pattern that was remarkably similar to that of normal vocal folds. The implanted side showed good mucosal amplitude and an intact mucosal wave. The implanted side appeared to be slightly thicker than the control side, giving the impression of greater mass. All the specimens were capable of stable periodic oscillations. The operated sides had the appearance of greater mass, but were equal in amplitude, mucosal wave, and vibratory capability to the control side. These differences were occasionally noted between the two sides. The operated side, being greater in mass, appeared to have a delay in the phase of vocal fold vibration compared to the opposite side. In all the preparations, the vocal fold amplitude was rated as the same as or greater than that of the nonoperated side. However, the degree to which apparent mass was added to the vocal folds showed considerable variation, which could not be accounted for by the size of the surgical implant placed into the pocket. Figure 1 is a series of videostroboscopy images for specimen 2. The glottal cycle shows a good vibratory amplitude, a symmetric phase of vibration, and an intact mucosal wave on both the control and implanted sides. The implanted side (right) has a slightly greater mass than the control side. The increased mass of the vocal fold may account for the increased subglottic pressure thresh-




Fig 1. (Specimen 2) Stroboscopic sequences. Flow rate was 300 mL/s, subglottic pressure was 12 cm H<sub>2</sub>O, and frequency was 82 Hz. Implanted side (arrow) has vibratory amplitude and wave, with some increase in mass.


Fig 2  
nous  
tissue  
betw  
aspe  
pare  
view

old

H  
iden  
fied  
was  
fold  
right  
the v  
fold  
to th  
place  
cons  
fibr  
view  
the s  
twee  
lium

Th  
adds  
scarr

Fig 2. (Specimen 1) Low-power midmembranous views of both vocal folds. Implanted tissue is combination of fat and fibrous tissue between arrows. Site of implant is on superior aspect of vocal fold. Increase in bulk compared to control side is seen on this low-power view.



old compared to normal canine larynges.

**Histologic Findings.** In all 6 specimens, clearly identifiable fat cells or fibrous tissue could be identified in the submucosal pocket. The fat component was present along the superior surface to the vocal fold edge. Figure 2 is a histologic section of both the right and left vocal folds in specimen 1. A close-up of the viable fat cells in the superior surface of the vocal fold is seen on Fig 3. The increase in bulk compared to the control side is evident. The finding of fat placement on the superior aspect of the vocal fold was consistent in all specimens. The amounts of fat and fibrous tissue were variable. Figure 4 is a close-up view of another specimen showing viable fat cells in the submucosal plane. The added fat cells are between the vocalis muscle and the vocal fold epithelium, increasing the thickness of Reinke's space.

DISCUSSION

The use of fat as a soft tissue implant in the larynx adds an exciting prospect in the rehabilitation of the scarred larynx. Fat augmentation in soft tissue recon-

struction has a long history. Use of fat in the vocal fold as an autologous substitute for soft tissue has been proposed.<sup>4-6</sup> The initial experience of fat injection was the use of fat as an augmentation substitute for Teflon in the rehabilitation of the paralyzed vocal fold. Wetmore<sup>7</sup> studied fat injection in the rabbit model and compared it to fat implantation. He showed reabsorption of injected fat over the first year. Although viable fat was shown histologically, the amount was variable. Histologic examination of injected fat showed cyst formation indicative of fat cell degeneration. In a study of human patients undergoing fat injection for vocal fold paralysis, Zaretsky et al<sup>6</sup> supported the findings of retained viable fat, but pointed to the rapid absorption of fat over the first 6 months after surgery. Fat is believed to be absorbed principally because of the processing technique used to prepare fat for injection. Fat implantation may obviate the need for fat processing and cell necrosis. The use of fat implantation has a long history of use in facial plastic surgery. Fat implantation has less absorption than fat injection. Fat injection versus fat implantation was submitted to volumetric and histo-

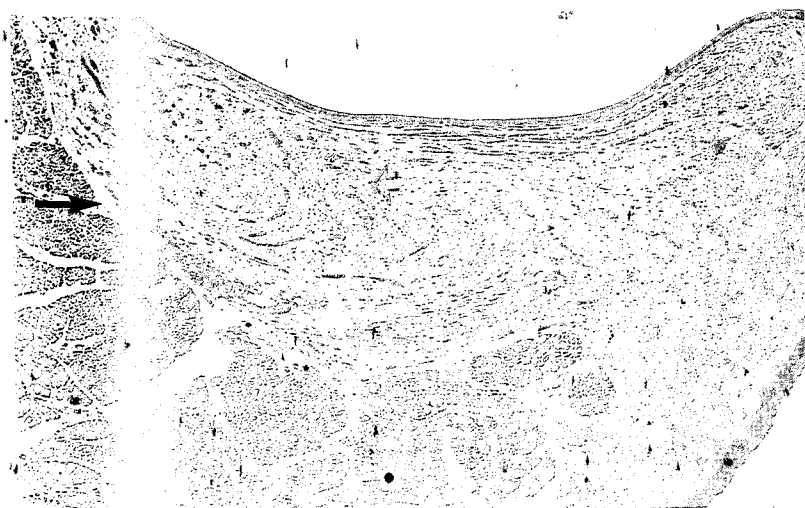


Fig 3. (Specimen 1) Close-up view. Collagen (open arrow) and fibrous tissue sit above fat layer (closed arrow). Buccal fat pad in dog has variable fibrous and fatty tissue, which may explain mixed picture.

he  
re-  
ine  
the  
es-  
20  
us-  
ine  
10  
d a  
hat  
ed  
ve.  
ker  
ter  
ri-  
ar-  
de,  
rol  
ted  
ing  
ase  
de.  
vas  
the  
ich  
ed  
ted  
the  
py  
s a  
v-  
the  
ide  
rol  
ray  
sh-

ces.  
sure  
Hz.  
pli-  
ass.

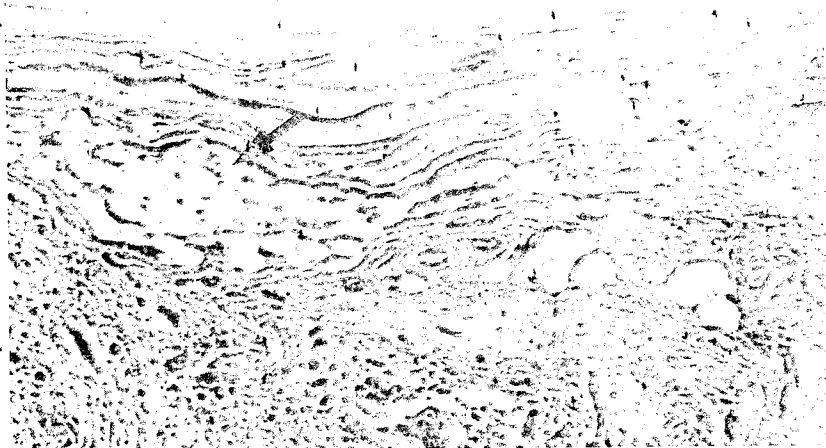


Fig 4. High-power view of viable fat cells (arrow) in Reinke's space.

logic study in the rabbit by Kononas et al,<sup>12</sup> who found that less reabsorption occurs with implantation.

In rehabilitation of the scarred vocal fold, the stiff submucosal plane is devoid of the fluidlike layer in Reinke's space. This stiff layer reduces vocal cord vibration and is responsible for the nonvibratory segment seen in patients with scarred vocal folds. The scar does not participate in vocal fold oscillation. In rehabilitation of such a problem, the surgeon has few choices at present. Isshiki<sup>13</sup> describes surgical mucosal grafting in patients who have no vibratory capacity by thyrotomy, mucosal grafting, tracheostomy, and endolaryngeal stenting. Ford<sup>3</sup> has treated patients with vocal fold scarring by collagen injection to correct glottic deficiencies. The use of fat as an injected material was evaluated by Mikus et al<sup>4</sup> in a canine study. They were able to show the presence of viable fat in the submucosal plane in dogs after fat injection. However, in the clinical situation, fat injection into the submucosal plane is complicated by the scarred bed.

In patients with vocal fold scars, fibrosis would make injection of fat into the submucosal layer a difficult procedure. Attempted injection of fat into a stiff vocal fold may result in fat's being deposited with little predictability: deep into the muscle, into the vocal fold ligament, or in other unwanted areas. A more predictable solution would be the surgical creation of a submucosal pocket by scar lysis followed by surgical implantation of fat to recreate the viscoelastic properties of the vocal fold. Our technical study evaluated an endoscopic approach for fat implantation into the canine vocal fold.

In a search for better autologous substances that simulate the viscoelastic properties of the human vocal fold, many substances have been tried. Theoretically, the material should be biocompatible and

simulate the viscoelastic properties of the multilayered vocal folds. It should also be readily available. Fat is a natural substance that is readily available for transplantation. Fat is an autologous implant with little to no donor site morbidity. It has a long history of use in facial plastic and reconstructive surgery. The viscoelastic properties of fat are closer to those of the fluidlike superficial layers of the vocal fold than are those of collagen or Teflon.

Endoscopic fat implantation in the vocal fold has not been done in humans. Wexler et al,<sup>8</sup> in a study of vocal fold scarring in the dog, showed conclusively that the scarred vocal fold failed to vibrate with the same subglottic pressure threshold and the same vibratory characteristics as in control animal models. The vibration was characterized by aperiodicity, high subglottic pressure, and reduced glottic efficiency. Further, the researchers showed that fat implanted into the vocal folds was able to reduce the subglottic pressure needed to set the vocal folds into stable periodic oscillation. The fat survival in Reinke's layer was carefully documented.

The advantages of fat implantation over fat injection are threefold. First, creation of a pocket allows the surgeon to lyse the scar and precisely place the implant where it is most needed, ie, near the vocal fold edge, rather than deep into the vocalis or vocal ligament. Second, the fat can be harvested and placed as a single implant without needing to be crushed. This should reduce fat cell lysis and necrosis. Third, the single implant should be able to create a single-layer, pliable fat cushion that is softer than the original scar, yet is a complete, uniform layer. A single, uniform layer of fat should be better than multiple droplets of fat cells injected into the area.

The disadvantages of fat implantation by the open laryngotomy approach are its technical difficulty and the need for thyrotomy. Open procedures require

trache  
talizat  
ated b  
study.

This  
in fin  
impla  
but co  
fold o  
1) fat  
into th  
2) sur  
mente  
3) str  
impro  
ties of  
compe  
surger  
compl  
of fat i  
this ne

This  
implar  
techni  
been a  
presen  
Howev  
tinue t  
6 week  
be dor  
specim  
the dog  
fat abe  
conver  
used w  
the tec  
for fat i  
scarrec  
al.<sup>8</sup>

The

1. W  
treatme  
retrospe  
1084-91

2. H  
vibration  
College

3. F  
In: Ford  
ment of v  
41.

4. M  
tioned ar  
fold. Lai

tracheostomy, laryngofissure, and prolonged hospitalization. Many of these disadvantages may be obviated by an endoscopic approach, as attempted in this study.

This study, using endoscopic techniques, resulted in findings similar to those of Wexler et al.<sup>8</sup> The implanted fat added bulk and mass to the vocal fold, but continued to be pliable and participate in vocal fold oscillation. The conclusions from this study are 1) fat and fibrous tissue can be successfully placed into the Reinke's layer by an endoscopic technique, 2) survival of the fat and fibrous tissue was documented at 6 weeks after surgery on histologic section, 3) stroboscopic findings after fat implantation show improved tissue bulk, and 4) the vibratory capabilities of the vocal folds augmented by fat implants were comparable to those of the control side. If the goal of surgery for vocal fold scarring is the restoration of compliant vocal folds capable of oscillation, the use of fat implanted in the vocal fold cover should satisfy this need.

This study of fat survival after endoscopic fat implantation should be considered preliminary. The technical aspects of endoscopic fat implantation have been addressed only partially by this study. The presence of fat survival at 6 weeks is encouraging. However, whether fat survival will persist and continue to augment the vocal fold cover after the initial 6 weeks is not clear. Longer survival studies should be done. The presence of fibrosis in the histologic specimens suggests that either the buccal fat pad in the dog is not a good source for fat, or there is some fat absorption in the implant site, with fat being converted into autologous collagen. The animal model used was not a scarred laryngeal model. Because of the technical aspects of developing new techniques for fat implantation, no attempt was made to simulate scarred vocal fold conditions as done by Wexler et al.<sup>8</sup>

The technical aspects of creation of an optimal flap

to receive the fat have not been addressed. In the canine experiments, the fat was limited to the superior and medial edges of the vocal fold. The undersurface of the vocal folds did not receive the implants. Where the fat should be placed to achieve optimal vibration is not clear. Whether the fat should be placed on the undersurface, the free vocal fold edge, the superior edge, or a combination of all is not certain. This will need to be further studied. This study did not quantify the amount of fat absorption after implantation, because of the variations in specimen size and the difficulty of volumetric studies. A statistical analysis based on volumetric studies from serial sections would be ideal.

Despite these limitations, the further development of a practical endoscopic approach to the scarred vocal fold should allow the phonosurgeon more options in the treatment of the postoperatively dysphonic patient. Fat implantation, mucosal grafting, and scar revision, if it can be done endoscopically, should advance the current treatment options for the scarred vocal fold. The histologic and stroboscopic results from this preliminary study are encouraging. Although further work is needed to determine the optimal site of fat implantation, we believe fat implantation into the lamina propria of the vocal folds is a feasible approach. Further studies are needed to document the surgical validity of fat in a scarred animal model.

In summary, we have used an endoscopic approach for fat implantation and augmentation of the canine vocal fold. Endoscopic evaluation, stroboscopic assessment of vibratory function, and histologic examination show retention of bulk and vibratory behavior. The placement of fat into Reinke's space serves as an autologous implant for restoration of Reinke's layer. These encouraging results suggest that fat implantation via the endoscopic approach may be feasible in the human for rehabilitation of the scarred vocal fold.

## REFERENCES

1. Woo P, Casper J, Colton R, Brewer D. Diagnosis and treatment of persistent dysphonia after laryngeal surgery: a retrospective analysis of 62 patients. *Laryngoscope* 1994;104:1084-91.
2. Hirano M, Kakita Y. Cover-body theory of vocal cord vibration. In: Daniloff RG, ed. *Speech science*. San Diego, Calif: College Hill Press, 1985:1-46.
3. Ford C. Laryngeal injection techniques in phonosurgery. In: Ford CM, Bless DM, eds. *Assessment and surgical management of voice disorders*. New York, NY: Raven Press, 1991:123-41.
4. Mikkelson L, Koufman JA, Kilpatrick SE. Fate of liposuctioned and grafted autologous fat injections in the canine vocal fold. *Laryngoscope* 1995;105:17-22.
5. Brandenburg JH, Kirkham W, Koschke D. Vocal cord augmentation with autogenous fat. *Laryngoscope* 1992;102:495-500.
6. Zaretsky LS, Shindo ML, deTar M, Rice DH. Autologous fat injection for vocal fold paralysis: long-term histologic evaluation. *Ann Otol Rhinol Laryngol* 1995;104:1-4.
7. Wetmore SJ. Injection of fat for soft tissue augmentation. *Laryngoscope* 1989;99:50-7.
8. Wexler DB, Jiang J, Gray SD, Titze IR. Phonosurgical studies: fat-graft reconstruction of injured canine vocal cords. *Ann Otol Rhinol Laryngol* 1989;98:668-73.
9. Jiang J, Titze IR, Wexler DB, Gray SD. Fundamental frequency and amplitude perturbation in reconstructed canine

vocal folds. *Ann Otol Rhinol Laryngol* 1994;103:145-8.

10. Woo P, Casper J, Griffin B, Colton R, Brewer D. Endoscopic microsuture repair of vocal fold defects. *J Voice* 1995; 9:332-9.

11. Baer T. Investigation of phonation using excised larynges [Dissertation]. Cambridge, Mass: Massachusetts Institute of Technology, 1975.

12. Kononas TC, Bucky LP, Hurley C, May JW. The fate of suctioned and surgically removed fat after implantation for soft tissue augmentation: a volumetric and histologic study in rabbit. *Plast Reconstr Surg* 1993;91:763-6.

13. Isshiki N. Surgical management of scar of the vocal cord in phonosurgery: theory and practice. Berlin, Germany: Springer Verlag, 1989:175-9.

INTERNATIONAL CONFERENCE ON NEWBORN HEARING SCREENING DIAGNOSIS AND INTERVENTION

The International Conference on Newborn Hearing Screening Diagnosis and Intervention will be held in Milan, Italy, October 12-14, 2000. In Europe, contact Dr Ferdinando Grandori, Center of Biomedical Engineering, Polytechnic of Milan, piazza Leonardo da Vinci 32, I-20133 Milan, Italy; fax +39.02.2399.3360; e-mail NHS2000@biomed.polimi.it. In the United States, contact Dr Deborah Hayes, The Children's Hospital, 1056 E 19th Ave, B030, Denver, CO 80218; telephone (303) 861-6424; fax (303) 764-8220; e-mail Hayes.deborah@tchden.org.

IN

In so  
to be pe  
estimate  
that "cra  
making t  
rated foc

KEY

Like  
uppubl  
of tota  
through  
cause o  
these e  
tulated  
sible. I  
cannot  
dle ear  
of the  
break i

This  
ing the  
the foc  
mean a  
with a

For e  
plate, e  
tempor  
that en  
easily c  
than im  
This is  
between  
the non  
"static"  
ment o  
ducted  
ments

From  
CO  
180