

# Case Report

## Oropharyngeal Teratoma: Prenatal Diagnosis and Assessment Using Sonography, MRI, and CT with Management by Ex Utero Intrapartum Treatment Procedure

Diane Morof<sup>1</sup>, Deborah Levine<sup>1,2</sup>, Ian Grable<sup>1</sup>, Carol Barnewolt<sup>3,4</sup>, Judy Estroff<sup>3,4</sup>, Steven Fishman<sup>4,5</sup>, Reza Rahbar<sup>5,6</sup>, Rusty W. Jennings<sup>4,5</sup>

Oropharyngeal teratomas are rare congenital tumors with an estimated incidence of one in 35,000 to one in 200,000 live births [1]. We present a case of an oropharyngeal teratoma identified by an elevated level of maternal serum  $\alpha$ -fetoprotein at 16 weeks with sonographic diagnosis at that time. The tumor was bilobed; it originated in the oropharynx and protruded through a distended jaw into the amniotic fluid. This report describes serial imaging studies during the pregnancy including sonography, MRI, and CT with delivery by the ex utero intrapartum treatment (EXIT) procedure.

### Case Report

The patient is a 30-year-old gravida 4, para 1 woman with no significant medical history. She was found at 16 weeks to have an elevated level of serum  $\alpha$ -fetoprotein at 4.3 multiples of the median. A sonogram of the fetus revealed a 1-

cm right facial mass. The patient was referred to Beth Israel Deaconess Medical Center where sonography (ATL HDI 5000 SonoCT, ATL) and MRI (Symphony, Siemens) with the half-Fourier single-shot rapid acquisition with relaxation enhancement technique were performed. Sonograms showed a mass arising from the right cheek with an extrinsic hypovascular cystic and solid component freely floating in the amniotic fluid (Fig. 1A). MR images showed a component of the mass in the oropharynx (Fig. 1B). The intracranial anatomy was normal.

Patient counseling regarding fetal airway obstruction at birth was performed at Boston Children's Hospital where repeated sonography and MRI (TwinSpeed, GE Healthcare) at 20 weeks showed that the portion of the mass floating in the amniotic fluid had increased to 3.5 cm.

At 27 weeks, the patient was admitted in preterm labor. Repeated imaging revealed that the mass had increased to 10 cm in greatest dimension (Figs. 1C–1E) with an amniotic fluid index

of 32 cm. The fetal stomach was small, suggesting that the fetus was having difficulty swallowing. The fetal mouth was persistently open because of the large size of the mass in the oropharynx. The lower and mid regions of the trachea were well visualized. However, in the region of the pyriform sinus and proximal trachea, only soft tissue was seen. The mandible appeared thin adjacent to the tumor. A CT scan was obtained to exclude the possibility of bone invasion with the thought that if bone destruction was present, delivery would be performed as soon as possible to prevent further facial destruction. The position of the fetal head was noted on sonography to limit the radiation dose. This area was then placed in the center of the CT scanner and 19 slices of 5-mm thickness were obtained. Total fetal exposure was 0.00651 Gy (651 mrad). Images were reconstructed at 1.5-mm intervals in the fetal sagittal, coronal, and axial planes. The fetal mouth was wide open because of the tumor, and some mandibular and maxil-

Received November 10, 2003; accepted without revision November 18, 2003.

<sup>1</sup>Department of Obstetrics and Gynecology, Beth Israel Deaconess Medical Center, Boston, MA 02215.

<sup>2</sup>Department of Radiology, Beth Israel Deaconess Medical Center, 330 Brookline Ave., Boston, MA 02215. Address correspondence to D. Levine (dlevine@caregroup.harvard.edu).

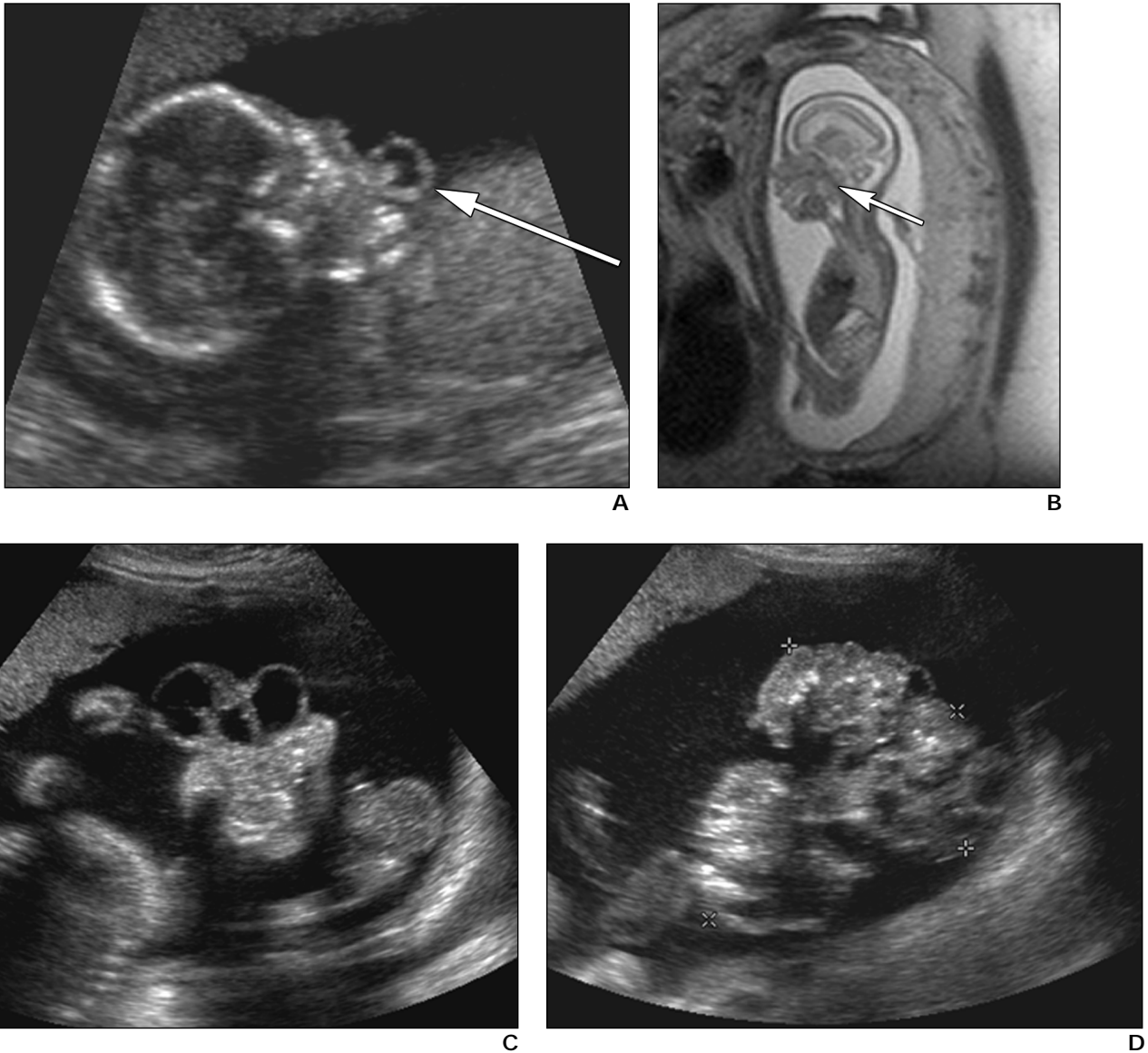
<sup>3</sup>Department of Radiology, Children's Hospital, Boston, MA.

<sup>4</sup>Advanced Fetal Care Center, Children's Hospital, Boston, MA.

<sup>5</sup>Department of Surgery, Children's Hospital, Boston, MA.

<sup>6</sup>Department of Otolaryngology, Children's Hospital, Boston, MA.

AJR 2004;183:493–496 0361–803X/04/1832–493 © American Roentgen Ray Society



**Fig. 1.**—30-year-old gravida 4, para 1 woman with no significant medical history. She was found at 16 weeks to have elevated level of serum  $\alpha$ -fetoprotein. **A**, Oblique sonogram of fetus at 16 weeks' gestational age shows 1-cm mass (*arrow*) projecting from right cheek into amniotic fluid. **B**, Sagittal half-Fourier single-shot RARE MR image (TR/TE, single shot/60; field of view, 30  $\times$  30 cm; matrix, 192  $\times$  256; slice thickness, 3 mm) of fetus at 16 weeks' gestational age shows internal component of mass distending oropharynx (*arrow*). **C** and **D**, Coronal sonogram of nose and lips of fetus at 28 weeks' gestational age (**C**) and axial sonogram of mass (*callipers*, **D**) show 10-cm mass extending into amniotic fluid. (*Fig. 1* continues on next page)

lary bone erosion without invasion was detected (Fig. 1F).

At 29 weeks, the patient had a recurrent episode of preterm labor. Her cervical length was 1.4 cm. She had severe polyhydramnios with an amniotic fluid index of 40 cm. Therapeutic amniocentesis (1,600 mL of amniotic fluid) was performed. The karyotype was normal, and cytology revealed no malignant cells.

At 31 weeks, the patient continued to have preterm labor. Because a well-controlled, planned

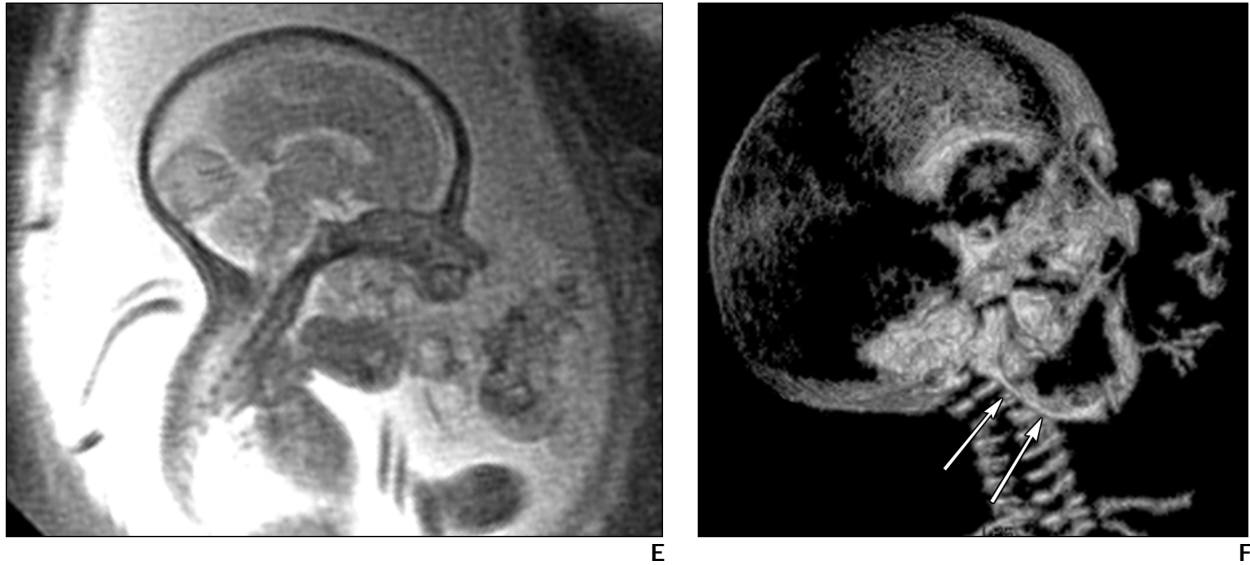
delivery was necessary, an EXIT procedure was planned for delivery. Immediately before the procedure, repeated MRI depicted the patency of the trachea. In addition, a nuchal cord was noted, with 1.5 loops of umbilical cord around the neck and the second loop extending over the shoulder (Fig. 1G).

During the EXIT procedure, while the fetus remained attached to the placental circulation, a nuchal and left shoulder cord was found, but it could not be reduced because of the size and

location of the tumor mass. After delivery of the fetal head, it was decided that intubation was not feasible, and a tracheostomy tube was placed. Fluid was removed from the lungs, surfactant was administered, the umbilical cord was clamped and divided, and the infant was delivered and taken to an adjacent operating room (Fig. 2).

At surgery, the large pedunculated mass extended from the right buccal mucosa and palatal region, protruding from the oral cavity.

## Prenatal Diagnosis of Oropharyngeal Teratoma

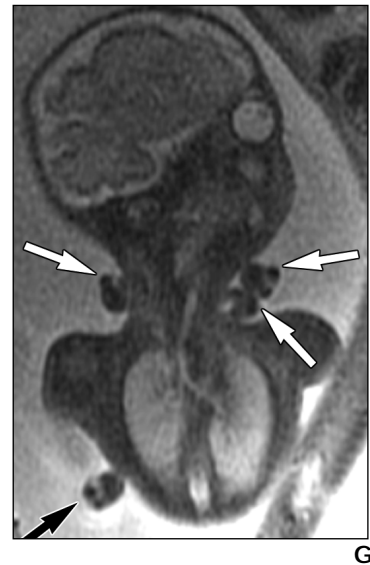


**Fig. 1. (continued)**—30-year-old gravida 4, para 1 woman with no significant medical history. She was found at 16 weeks to have elevated level of serum  $\alpha$ -fetoprotein.

**E,** Sagittal half-Fourier single-shot RARE MR image (single shot/60; field of view,  $30 \times 30$  cm; matrix,  $256 \times 256$ ; slice thickness, 4 mm) of fetus at 28 weeks' gestational age shows oral cavity portion of mass, which was not well visualized sonographically. Mouth was persistently in open position because of size of mass.

**F,** Three-dimensional CT reconstruction of fetal face at 29 weeks' gestational age shows mouth is in open position. Mandible (*arrows*) is thinned, and bones are deformed; however, no bone invasion is noted.

**G,** Coronal half-Fourier single-shot RARE MR image (single shot/82.9; field of view,  $40 \times 40$  cm; matrix,  $384 \times 256$ ; slice thickness, 5 mm) of fetus at 31 weeks' gestational age depicts neck and chest immediately before ex utero intrapartum treatment procedure was performed. Trachea in mid neck extending to carina is well visualized. In addition, nuchal cord is noted, with 1.5 loops of umbilical cord around neck (*white arrows*) and with second loop extending over shoulder (*black arrow*).



Most of the mass was attached by a small stalk to the buccal mucosa and was resected with a small amount of residual mass. A second procedure at 60 days of life and a third procedure at 131 days were performed to resect the remainder of the mass, after which no gross tumor remained and no additional lesions were identified. At age 1 year, the infant is doing well, tolerating adequate oral intake and gaining appropriate weight.

The pathology of the tumor was immature teratoma without malignant elements.

### Discussion

Teratomas are tumors composed of all three germ cell layers and represent 25–35% of all neonatal tumors. Teratomas can be found from

the head to the pelvis along the midline of the body but occur most commonly in the sacro-coccygeal region [2]. Teratomas of the head and neck represent approximately 6–10% of all teratomas and are most often found in the cervical region, followed by the nasopharynx and oropharynx.

Oropharyngeal teratomas are rare [1]. They grossly appear as heterogeneous masses with solid and cystic components and are believed to result from a migration and entrapment of mesoderm and endoderm with ectoderm during embryogenesis of the oral cavity [3].

This case presented classically with an elevated level of maternal serum  $\alpha$ -fetoprotein, a facial mass, and polyhydramnios [4]. Similar to other researchers who have reported many

complex congenital abnormalities involving airway management [5–7], we found MRI to be helpful for counseling and management. Fetal MRI was helpful for excluding brain involvement, revealing the extent of oropharyngeal involvement, defining tracheal anatomy in preparation for tracheostomy, and showing the nuchal and shoulder cord that caused problems during the EXIT procedure.

CT is rarely indicated for assessment of fetal abnormalities. CT studies have revealed calcifications in approximately 16% of postnatal teratoma cases and can be helpful in the determination of bone involvement that could change surgical management [8]. In our case, fetal CT was performed for evaluation of potential bone invasion. If in-

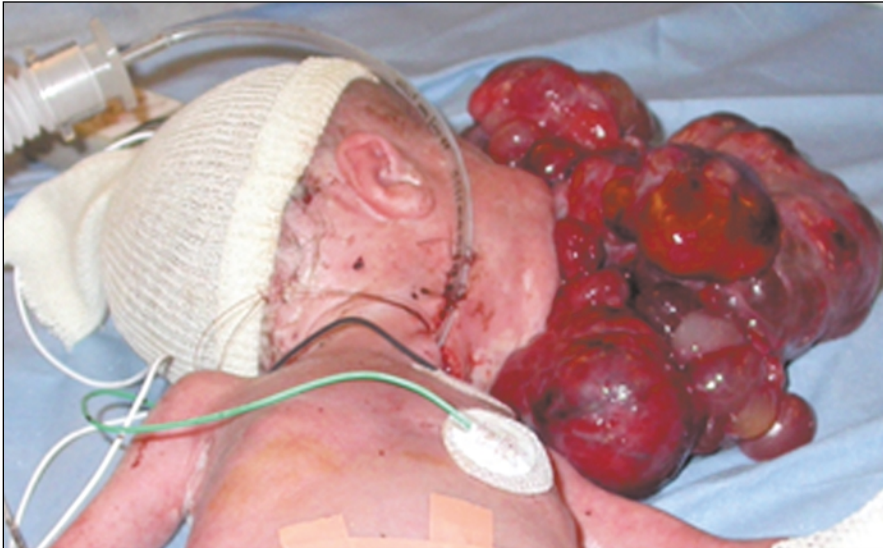

Fig. 2.—Photograph of female neonate at time of delivery shows tracheostomy tube and large oropharyngeal teratoma.

vasion had occurred, delivery would have been performed as soon as possible to allow optimal facial preservation. Sonography performed before CT was helpful in appropriately positioning the patient to limit the fetal radiation dose.

#### Conclusion

This case describes the in utero diagnosis and outcome for a fetus with an oropharyngeal teratoma delivered by the EXIT procedure. The combination of sonography, MRI, and CT for evaluation of tumor character, location, and size was essential for determining the timing and

mode of delivery. This information was critical for counseling the parents with regard to the outcome and coordinating maternal and fetal health care teams.

#### References

1. Smith NM, Chambers SE, Billson VR, Laing I, West CP, Bell JE. Oral teratoma (epignathus) with intracranial extension: a report of two cases. *Prenat Diagn* 1993;13:945–952
2. Askin DF. Neonatal cancer: a clinical perspective. *J Obstet Gynecol Neonatal Nurs* 2000;29:423–431
3. Kountakis SE, Minotti AM, Maillard A, Stierberg CM. Teratomas of the head and neck. *Am J Otolaryngol* 1994;14:292–296
4. Clement K, Chamberlain P, Boyd P, Molyneux A. Prenatal diagnosis of an epignathus: a case report and review of the literature. *Ultrasound Obstet Gynecol* 2001;18:178–181
5. Sichel JY, Gomori JM, Ezra Y, Eliashar R. Prenatal magnetic resonance imaging of a cervical lymphangioma for assessment of the upper airway. *Ann Otol Rhinol Laryngol* 2002;111:464–465
6. Kathary N, Bulas DI, Newman KD, Schonberg RL. MRI imaging of fetal neck masses with airway compromise: utility in delivery planning. *Pediatr Radiol* 2001;31:727–731
7. Hubbard AM, Harty MP. MRI for the assessment of the malformed fetus. *Baillieres Best Pract Res Clin Obstet Gynaecol* 2000;14:629–650
8. Gundry SR, Wesley JR, Klein MD, Barr M, Corran AG. Cervical teratomas in the newborn. *J Pediatr Surg* 1983;18:382–386