

# Mucoepidermoid Carcinoma of the Parotid Gland in Children

## A 10-Year Experience

Reza Rahbar, DMD, MD; J. Fredrik Grimmer, MD; Sara O. Vargas, MD; Caroline D. Robson, MB, ChB; Jennifer W. Mack, MD; Antonio R. Perez-Atayde, MD; Karen J. Marcus, MD; Holcombe E. Grier, MD; Gerald B. Healy, MD; Trevor J. McGill, MD

**Objective:** To determine the presentation, pathologic features, treatment outcome, and prognosis of mucoepidermoid carcinoma of the parotid gland in children.

**Design:** Retrospective clinical and histopathologic study with institutional review board approval.

**Setting:** Tertiary pediatric medical center.

**Patients:** Seven children (4 girls and 3 boys) presented with mucoepidermoid carcinoma of the parotid gland between 1994 and 2004.

**Main Outcome Measures:** Clinical presentation, pathologic features, treatment outcome, complications, local recurrence, distant metastasis, and overall survival.

**Results:** All patients presented with an asymptomatic parotid mass. Initial treatment in 7 patients included total parotidectomy (n=3), superficial parotidectomy (n=3), transoral enucleation (n=1), and supraomohyoid neck dissection (n=1). Four patients required additional sur-

gical procedures because of a close and/or positive margin, including revision parotidectomy (n=2), total parotidectomy (n=1), superficial parotidectomy (n=1), and supraomohyoid neck dissection (n=1). One patient required postoperative radiation therapy. No evidence of local recurrence or distant metastasis was noted with a mean follow-up of 3.4 years.

**Conclusions:** Mucoepidermoid carcinoma of the parotid gland is very rare in children. Clinical stage and histologic grade are the main prognostic factors. Complete excision (superficial or total parotidectomy) with preservation of facial nerve is the treatment of choice. Neck dissection should be considered when there is clinical evidence of regional metastasis, high TNM stage, high histologic grade, and involvement of regional nodes. Because of the possibility of long-term adverse effects in pediatric patients, radiotherapy should be used only in selected cases. Long-term follow-up is essential to rule out late recurrence.

*Arch Otolaryngol Head Neck Surg.* 2006;132:375-380

**N**EOPLASMS OF SALIVARY glands are rare in children, representing fewer than 10% of all pediatric head and neck tumors.<sup>1</sup> Approximately 80% of salivary gland tumors are considered benign, pleomorphic adenoma being the most common type.<sup>2</sup> Mucoepidermoid carcinomas account for 50% of malignant salivary gland tumors in children.<sup>3,4</sup> Other malignant salivary gland tumors include adenoid cystic carcinoma, undifferentiated carcinoma, and acinic cell carcinoma, each of which occurs at a frequency of approximately 5% to 10%.<sup>5</sup>

Because of the rarity of salivary gland malignancies in children and the array of different histopathologic types, it has been difficult to accumulate a broad experience and to establish a standard treatment strategy. Herein, we present our experience with mucoepidermoid carcinoma of the pa-

rotid gland in the pediatric population and provide some guidelines for preoperative evaluation, management, and follow-up.

## METHODS

Patients who were treated at Children's Hospital, Boston, Mass, for mucoepidermoid carcinoma of the parotid gland between 1994 and 2004 were identified. Their medical charts were reviewed for clinical presentation, treatment modality, treatment outcome, complications, local recurrence, distant metastasis, and overall survival. Cross-sectional imaging studies were reviewed for size, location, and imaging characteristics of the lesions. Preoperative imaging studies were available for review in 4 of 7 cases. These examinations included computed tomography (CT) in 2 patients, magnetic resonance (MR) imaging in 1 patient, and both CT and MR image in 1 patient. The CTs consisted of 3- to 5-mm-thick axial images with contrast. The MR images included axial T1- and T2-weighted fat-suppressed or fast spin-echo

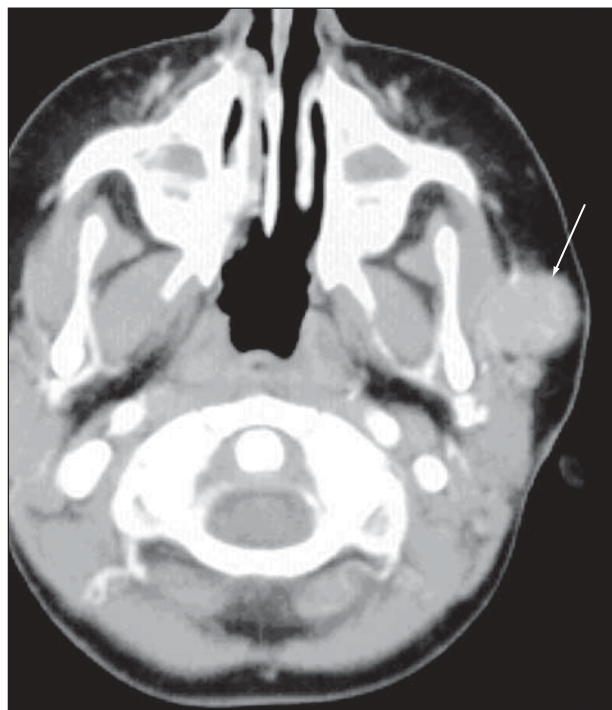
### Author Affiliations:

Departments of Otolaryngology (Drs Rahbar, Grimmer, Marcus, Healy, and McGill), Pathology (Drs Vargas and Perez-Atayde), Radiology (Drs Robson and Marcus), Oncology (Drs Mack and Grier), and Radiation Oncology (Dr Marcus), Children's Hospital, Harvard Medical School, Boston, Mass.

**Table. Characteristics in 7 Cases of Low-Grade Mucoepidermoid Carcinoma**

Patient No./ Sex/ Age, y	TNM Stage	Surgical Procedure	Margins	Procedure to Address Positive Margins	Follow-up, mo	Outcome	Complications and/or Need for Further Surgery
1/M/11	NA	Total parotidectomy, selective dissection	Positive	Revision parotidectomy	13	Disease free	Presented with recurrence 12 mo after surgery, treated with radiotherapy
2/F/11	T1N0M0	Superficial parotidectomy	Negative	None	28	Disease free	Frey syndrome
3/F/3	T2N0M0	Total parotidectomy	Negative	None	62	Disease free	Presented with lymphadenopathy 26 mo after surgery, underwent excisional biopsy (no tumor in specimen)
4/M/12	T2N0M0	Total parotidectomy	Positive	Revision parotidectomy and selective neck dissection	76	Disease free	None
5/M/14	T2N0M0	Transoral enucleation	Positive	Superficial parotidectomy	13	Disease free	
6/F/15	NA	Superficial parotidectomy	Negative	None	22	Disease free	Presented with lymphadenopathy 21 mo after surgery, underwent excisional biopsy (no tumor in specimen)
7/F/14	NA	Superficial parotidectomy	Positive	Total parotidectomy	48	Disease free	Frey syndrome

Abbreviation: NA, not available.



**Figure 1.** A 3-year-old girl with a left preauricular mass. An axial contrast-enhanced computed tomogram reveals a sharply defined, moderately enhancing mass (arrow) located along the course of the left parotid duct and abutting the superficial aspect of the left masseter muscle.

inversion recovery pulse sequences in the axial and coronal planes. Axial and coronal fat-suppressed gadolinium T1-weighted images were also obtained.

Pathologic review included in-house biopsy specimens as well as consultation slides from referring institutions. Pathologic investigations included gross examination and microscopic examination of hematoxylin-eosin- and, in a subset of

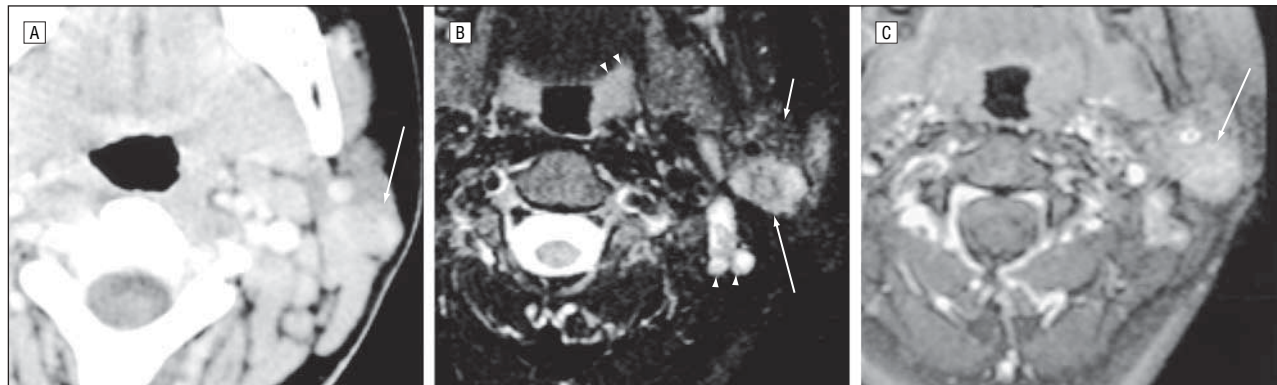
cases, mucicarmine-stained sections. A semiquantitative grading scheme<sup>6</sup> was applied.

## RESULTS

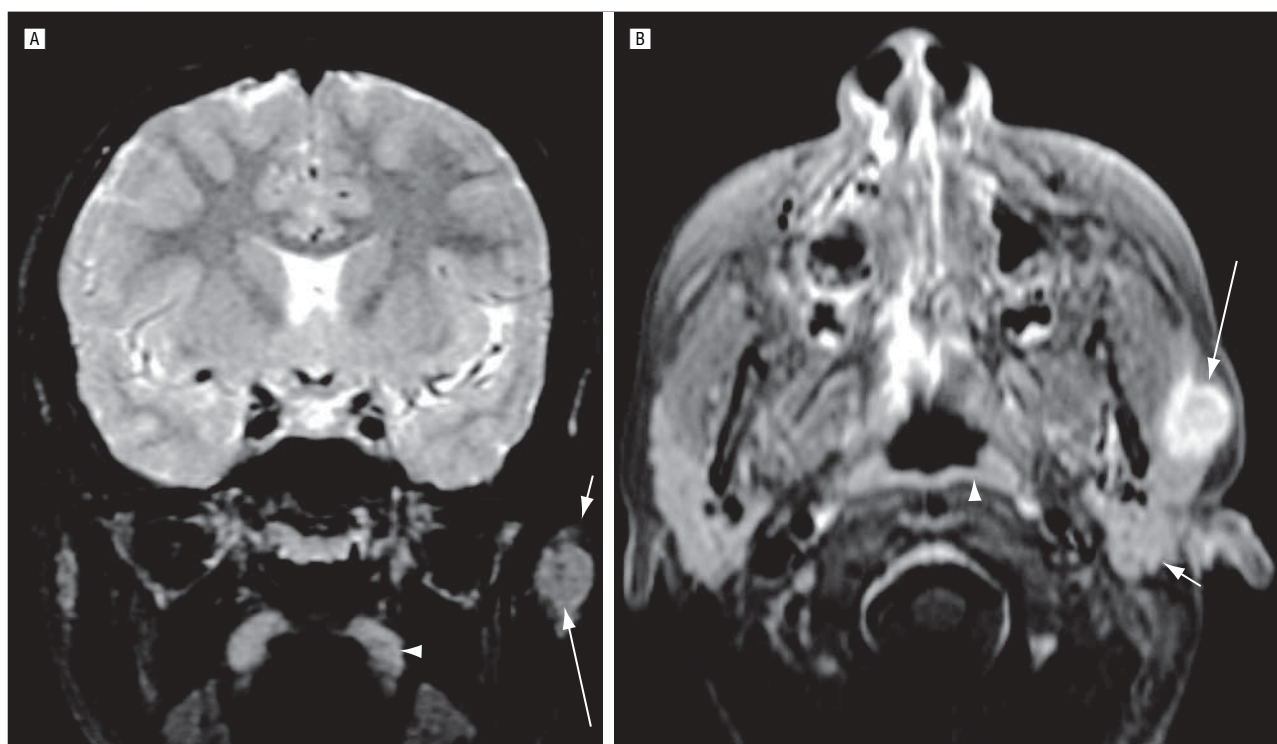
Seven patients (4 girls and 3 boys; age range, 3-15 years [mean age, 11.4 years]) were identified during the study period. Three patients presented to our institution initially (Nos. 2, 3, and 4; **Table**), and 4 patients received their initial surgical treatment at an outside facility (Nos. 1, 5, 6, and 7; **Table**). The duration of time from the onset of symptoms to surgery ranged from 2 weeks to 24 months, with an average duration of 9.5 months. All patients presented with an asymptomatic parotid mass (left, 5; right, 2). The results of clinical staging were as follows: T1N0M0 in 1 patient, T2N0M0 in 3 patients, and not available in 3 patients (**Table**). No patient presented with neck adenopathy, facial paralysis, or other cranial nerve deficits. There was no significant medical or family history in any of the cases.

## RADIOGRAPHIC FINDINGS

The tumors were located within the substance of the parotid gland in 2 of the patients and within accessory parotid tissue along the course of the parotid duct in 2 patients. On the CTs, the tumors appeared as moderately well-defined, moderately enhancing masses (**Figure 1** and **Figure 2A**). One tumor that was located within the parotid gland could not be distinguished from parotid space adenopathy, so MR image was performed to further characterize the mass (**Figure 2B** and **C**). In both cases, T2-weighted MR images revealed a moderately to markedly enhancing, well-defined mass that appeared hyperintense relative to parotid tissue but



**Figure 2.** An 11-year-old girl with a parotid mass. A, An axial contrast-enhanced computed tomogram demonstrates a moderately well-defined mass within the superficial and deep lobes of the left parotid gland (arrow). The characteristics of the mass appear similar to those of nearby lymph nodes. B, An axial fast spin-echo inversion recovery image reveals a heterogeneous tumor (long arrow) that appears hyperintense relative to adjacent parotid tissue (short arrow) but hypointense relative to lymphoid tissue (arrowheads) in lymph nodes and tonsils. C, After the administration of contrast, a fat-suppressed, axial T1-weighted magnetic resonance image reveals moderate enhancement of the tumor.



**Figure 3.** A 12-year-old boy with an enlarging left preauricular lump. A, A coronal fat-suppressed T2-weighted magnetic resonance image reveals an intermediate intensity mass (long arrow) within the superficial lobe of the parotid gland (short arrow), extending along the proximal parotid duct. The tumor is slightly hypointense compared with tonsillar lymphoid tissue (arrowhead). B, A fat-suppressed contrast-enhanced axial T1-weighted image reveals intense enhancement.

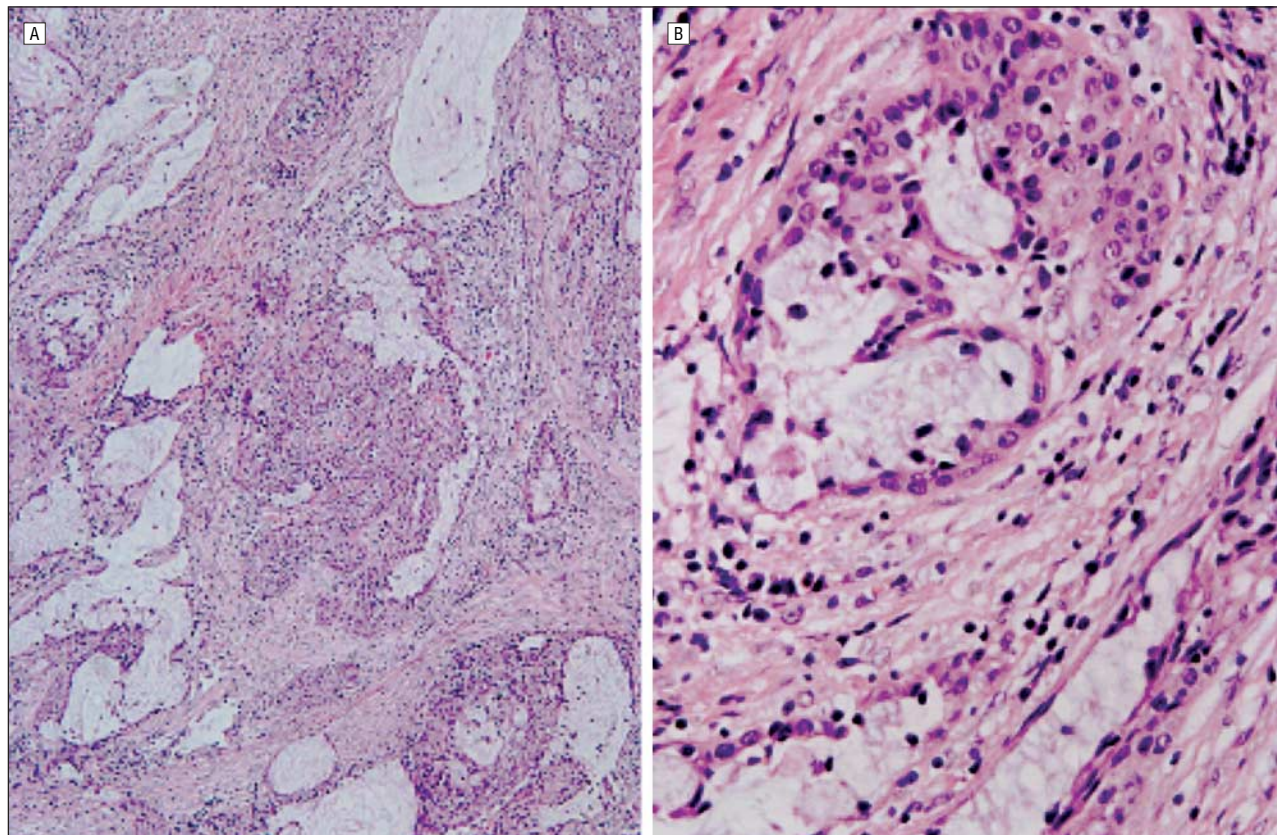
slightly hypointense relative to adjacent lymph nodes (Figure 2C and **Figure 3A**).

### TREATMENT

All patients underwent surgical extirpation for treatment. Initial treatment in 7 patients included total parotidectomy (n=3), superficial parotidectomy (n=3), transoral enucleation (n=1), and supraomohyoid neck dissection (n=1) (Table). Four patients (Nos. 1, 5, 6, and 7; Table) received their initial treatment at an outside institution. Four patients had close and/or positive margins and required additional surgical procedures, including revision parotidectomy (n=2), total parotidectomy

(n=1), superficial parotidectomy (n=1), and supraomohyoid neck dissection (n=1) (Table). All margins were negative after the second procedure.

One patient (No. 1) initially underwent total parotidectomy and selective neck dissection and required revision parotidectomy because of a positive margin. He presented with a recurrence 1 year later and was treated with conformal radiotherapy. He received 60 Gy of radiation using 6-MV photons in 30 fractions over 6 weeks. He tolerated the treatment well, with minimal mucosal and skin reaction. Another patient (No. 3) had undergone total parotidectomy. She developed neck lymphadenopathy 2 years after the initial treatment and underwent an excisional biopsy. No tumor was seen



**Figure 4.** The tumors were characterized by nests and cystic structures lined by squamoid, intermediate, and mucus-producing cells (hematoxylin-eosin, original magnification  $\times 100$  [A] and  $\times 400$  [B]).

histologically. A third patient (No. 6) had undergone superficial parotidectomy and presented with neck lymphadenopathy 21 months after surgery. Excisional biopsy revealed no evidence of recurrence. Two patients (Nos. 2 and 7) (29%) presented with mild gustatory sweating (Frey syndrome). No patient was treated with chemotherapy.

#### PATHOLOGIC, GROSS, AND MICROSCOPIC FINDINGS

Fine-needle aspiration in 1 case (patient 3) showed clusters of overlapping intermediate cells with large, irregularly round nuclei and prominent nucleoli. Occasional cells with abundant globular intracytoplasmic mucin and squamous cells were also noted. These findings strongly suggested a diagnosis of mucoepidermoid carcinoma.

Gross material was examined in the 3 cases in which the initial treatment was performed at our institution. The 3 specimens contained tan, lobular, well-circumscribed lesions measuring 1.9, 2.2, and 2.8 cm in greatest dimension. The material from referring institutions was fragmented in 2 cases and intact in 2 cases.

The tumors were characterized by nests and cystic spaces composed of or lined by intermediate or large polygonal epithelial cells with focal squamous differentiation or mucus secretion (**Figure 4**). In all cases, the cystic component made up more than 50% of the lesion, and all tumors were classified as low grade. Cellular atypia was minimal, and mitoses, perineural invasion, and necrosis

were not evident. Infiltration of soft tissue surrounding the salivary gland was seen in 6 of 7 cases. In 1 case (No. 5), the cells were oncocytic, in keeping with an oncocytic mucoepidermoid carcinoma. Mucicarmine stains highlighted mucin in all 3 cases in which the staining was performed. Margins of resection were positive in the initial resection specimens from 4 patients (Table).

#### COMMENT

Most salivary gland neoplasms occur in the parotid gland, followed by the submandibular gland. The characteristic presentation is that of a painless, slow-growing mass without any clinical indication of infection.<sup>1</sup> Clinical signs and symptoms appear to be of no value in distinguishing between malignant and benign tumors<sup>2</sup> unless there is pain, regional lymphadenopathy, or cranial nerve involvement, which may indicate an aggressive malignant process.<sup>3,7</sup>

In 1945, Stewart et al<sup>8</sup> recognized mucoepidermoid carcinoma of the salivary glands as a separate entity among salivary gland neoplasia. Mucoepidermoid carcinoma is thought to arise from pluripotent reserve cells of the excretory ducts of salivary gland that have the potential to differentiate into squamous, columnar, and mucous cells.<sup>9</sup> It is the most common parotid epithelial malignancy in children and usually occurs in the 5- to 15-year-old age group.<sup>7</sup> Although no specific etiologic factor has been identified, exposure to ionizing radiation has been reported in some cases.<sup>10</sup> Eveson and Cawson<sup>11</sup> reviewed 2410 salivary gland

tumors and indicated that only 6% of cases were diagnosed in the first 20 years of life, and the majority of these were diagnosed during adolescence. A review of the literature revealed a good prognosis in cases of mucoepidermoid carcinoma occurring in children, mainly because the majority of the tumors were well-differentiated or grade 1 neoplasia.<sup>12,13</sup> However, because of the rarity of this neoplasm, there is no broad experience with these tumors in the pediatric population, and most of the treatment strategies are based on experience with adults.

Proper preoperative evaluation is of paramount importance. Fine-needle aspiration is often difficult to perform in a very young child owing to a lack of cooperation; however, it can be useful in distinguishing between inflammatory, benign, and malignant processes. The accuracy of fine-needle aspiration ranges from 84% to 97% in malignant tumors of the salivary gland.<sup>14,15</sup> We believe that proper preoperative imaging and fine-needle aspiration, when possible, can facilitate preoperative surgical planning and prevent undertreatment and the need for revision surgery. Incisional biopsy is not recommended because of the risk of tumor spillage and facial nerve injury.

There is no consensus regarding the routine use of imaging studies in the adult population. However, we recommend preoperative imaging studies to determine the full extent of the tumor and to assess involvement of regional lymph node and possible tumor infiltration into adjacent structures. Compared with CT, MR imaging provides superior soft tissue differentiation and contrast resolution in the evaluation of parotid masses.<sup>16</sup> Both imaging modalities are susceptible to artifacts from dental fillings or braces, particularly in children.

The clinical and radiographic differential diagnosis of a parotid space mass includes other parotid tumors and masses involving lymphoid, neural, or vascular tissues in the parotid space. In children, the most common parotid tumor other than mucoepidermoid carcinoma is pleomorphic adenoma, which tends to have a higher signal intensity on heavily T2-weighted MR images.<sup>17</sup> Other parotid tumors that are occasionally encountered in children, and appear clinically and radiographically indistinguishable from mucoepidermoid carcinoma, include acinic cell carcinoma and adenocarcinoma. Parotid space vascular malformations (lymphatic or venous malformation) are readily differentiated from solid parotid tumors by clinical examination and imaging. Intraparotid hemangioma is the most common tumor of the parotid gland in infants and has very distinctive imaging features that distinguish it from other parenchymal tumors.

The histologic grade was low in all 7 of our cases. This finding is in keeping with a previous study of mucoepidermoid carcinoma at our institution, which showed a high rate of low-grade tumors.<sup>11</sup> This tendency likely accounts for the excellent outcomes seen in our and other pediatric series. In our study, we used a well-established grading system proposed by authors from the Armed Forces Institute of Pathology.<sup>6</sup> Given the lack of pleomorphism, mitoses, and necrosis, as well as the predominantly cystic architecture, all tumors in our series would also have been considered low grade in other classification systems.<sup>18</sup>

A number of authors have attempted to correlate clinical and pathologic aspects of salivary gland mucoepider-

moid carcinoma with prognosis.<sup>13,18-20</sup> Factors such as tumor grade, perineural invasion, lymph node metastasis, soft tissue extension, and microscopic residual disease have shown correlation with recurrence rates and survival.<sup>3,21,22</sup> Grade appears to be one of the most important prognostic indicators. When patients of all ages are considered, the published 5-year survival rates range from 92% to 100% in cases involving low-grade tumors, 62% to 92% in those involving intermediate-grade tumors, and 0% to 43% in those involving high-grade tumors.<sup>13,20,23-25</sup>

The treatment of choice should be complete removal of tumor with adequate margins. Although the relationship between the type of surgical treatment and survival is not known, it is clear that local and regional recurrence is more likely to occur in patients with positive margins, regardless of tumor grade.<sup>26</sup> There is continued debate with regard to the extent of parotidectomy (partial vs total). Superficial parotidectomy may be considered when the tumor is lateral to the facial nerve. Total parotidectomy is recommended when the deep lobe is involved or when there are positive intraparotid lymph nodes. Intraoperative frozen-section analysis can also help guide the extent of the surgery to prevent undertreatment. All efforts should be made to preserve the facial nerve. Sacrifice of the facial nerve should only be considered if the intact nerve limits total resection or if the nerve is directly invaded. Proper preoperative consideration should be given to facial nerve grafting if facial nerve resection is required.

The question of prophylactic neck dissection remains controversial. The overall incidence of lymph node metastases in primary parotid carcinomas ranges between 18 and 28%<sup>27,28</sup> when patients of all ages are considered. Spiro et al<sup>19</sup> have proposed a "staging" supraomohyoid neck dissection in patients with high-grade tumors and an elective radical neck dissection in patients with undifferentiated and squamous carcinomas. Frankenthaler et al<sup>29</sup> recommend performing a neck dissection only in cases in which there is a clinical or radiologic suspicion of lymph node metastases. Medina<sup>30</sup> proposed that elective neck dissection is indicated in cases involving T3 and T4 tumors, tumors larger than 3 cm, high-grade tumors, facial paralysis, patients older than 54 years, extraglandular extension, and perilymphatic invasion. Zbaren et al<sup>27</sup> advocate a routine elective neck dissection in all patients with primary carcinoma of the parotid gland. Pathologic examination of the neck dissection specimens did not show occult nodal metastasis in any of our patients. Based on our data and other reports in the literature,<sup>1</sup> it appears that elective neck dissection does not seem necessary in children with low-grade mucoepidermoid carcinoma of the parotid gland and clinically negative necks. However, if there is a positive intraparotid node, selective nodal dissection of high and midjugular nodes is recommended, even in the N0 neck. Neck dissection should be considered when there is clinical evidence of high TNM stage, high histologic grade, and involvement of regional nodes. A review of the literature reveals an overall 7% to 26% incidence of local recurrence, 3% to 16% incidence of regional metastasis, and 6% to 15% incidence of distant metastasis when all age groups are considered.<sup>13,19,24,31</sup> However, the majority of tumors presenting in younger patients (first to second decades of life) are low-grade lesions, which have a better prognosis.<sup>20,23,32</sup>

There are well-documented studies that demonstrate the efficacy of postoperative irradiation in local and regional control of salivary gland malignancy in patients of all ages.<sup>21,22</sup> However, the use of radiotherapy in children should be carefully considered because of the potential for long-term sequelae, which may occur in more than 50% of patients.<sup>1</sup> The indications for radiation therapy are (1) aggressive histologic features, such as perineural invasion, soft tissue extension, and multiple level involvement of neck adenopathy; (2) high-grade tumors; and (3) residual disease that is not resectable.<sup>1</sup> To minimize late sequelae, careful treatment planning with conformal techniques, such as intensity-modulated radiation therapy, should be used whenever possible. Potential long-term complications of radiotherapy are facial deformity, trismus, xerostomia, osteoradionecrosis, and secondary tumors.

The role of chemotherapy in the management of mucoepidermoid carcinoma remains incompletely defined but is generally reserved for patients with progressive local or metastatic disease that is not amenable to surgical or radiation therapy. While response rates of up to 50% have been reported, the duration of response is short, typically ranging from 6 to 12 months.<sup>33</sup> Adjuvant or neoadjuvant protocols have also been reported,<sup>33</sup> but with no definition of the role of chemoradiotherapy and in such small numbers that interpretation of results is difficult. Choice of agents is similarly hampered by the absence of large trials; however, high-grade mucoepidermoid carcinoma appears to be sensitive to agents that are effective in the treatment of squamous cell carcinomas, including cisplatin, bleomycin, methotrexate, and fluorouracil.<sup>33</sup>

## CONCLUSIONS

Mucoepidermoid carcinoma of the parotid gland is very rare in children. Clinical stage and histologic grade are the main prognostic factors. Complete excision (superficial or total parotidectomy) with preservation of facial nerve is the treatment of choice. Neck dissection should be considered when there is clinical evidence of regional metastasis, high TNM stage, high histologic grade, and involvement of regional nodes. Radiotherapy should only be used in selected cases because of the possibility of long-term adverse effects in children and young patients. Long-term follow-up is essential to rule out late recurrence.

**Submitted for Publication:** July 1, 2005; accepted September 7, 2005.

**Correspondence:** Reza Rahbar, DMD, MD, Department of Otolaryngology, Children's Hospital, 300 Longwood Ave, Boston, MA 02115 (reza.rahbar@childrens.harvard.edu).

**Financial Disclosure:** None.

**Previous Presentation:** This study was presented at the 20th Annual Meeting of the American Society of Pediatric Otolaryngology; May 28, 2005; Las Vegas, Nev.

## REFERENCES

- Callender DL, Frankenthaler RA, Luna MA, Lee SS, Goepfert H. Salivary gland neoplasms in children. *Arch Otolaryngol Head Neck Surg.* 1992;118:472-476.
- Chidzonga MM, Perez VML, Alvarez ALP. A clinicopathologic study of parotid tumors. *J Oral Maxillofac Surg.* 1994;52:1253-1256.
- Byers RM, Piorowski R, Luna MA. Malignant parotid tumors in patients under 20 years of age. *Arch Otolaryngol.* 1984;110:232-235.
- Schuller DE, McCabe BF. The firm salivary mass in children. *Laryngoscope.* 1977; 87:1891-1898.
- Shikhani AH, Johns ME. Tumors of the major salivary glands in children. *Head Neck Surg.* 1988;10:257-263.
- Goode RK, Auclair PL, Ellis GL. Mucoepidermoid carcinoma of the major salivary glands: clinical and histopathologic analysis of 234 cases with evaluation of grading criteria. *Cancer.* 1998;82:1217-1224.
- Baker SR, Malone B. Salivary gland malignancy in children. *Cancer.* 1985;55: 1730-1736.
- Stewart FW, Foote FW, Becker WF. Mucoepidermoid tumors of salivary glands. *Ann Surg.* 1945;122:820-844.
- Batsakis JG. Salivary gland neoplasia: an outcome of modified morphogenesis and cytodifferentiation. *Oral Surg Oral Med Oral Pathol.* 1980;49:229-232.
- Spitz MR, Batsakis JG. Major salivary gland carcinoma: descriptive epidemiology and survival of 498 patients. *Arch Otolaryngol.* 1984;110:45-49.
- Eveson JW, Cawson RA. Salivary gland tumours: a review of 2410 cases with particular reference to histological types, site, age and sex distribution. *J Pathol.* 1985;146:51-58.
- Gustafsson H, Dahlqvist A, Anniko M, Carlsoo B. Mucoepidermoid carcinoma in a minor salivary gland in childhood. *J Laryngol Otol.* 1987;101:1320-1323.
- Spiro RH, Huvos AG, Berk R, Strong EW. Mucoepidermoid carcinoma of salivary gland origin: a clinicopathological study of 367 cases. *Am J Surg.* 1978; 136:461-468.
- Zbaren P, Schar C, Hotz MA, Loosli H. Value of fine-needle aspiration cytology of parotid gland masses. *Laryngoscope.* 2001;111:1989-1992.
- Al-Khatfaji BM, Nestok BR, Katz RI. Fine-needle aspiration of 154 parotid masses with histologic correlation. *Cancer.* 1998;84:153-159.
- Weber AL, Romo L, Hashmi S. Malignant tumors of the oral cavity and oropharynx: clinical, pathologic, and radiologic evaluation. *Neuroimaging Clin N Am.* 2003; 13:443-464.
- Sakamoto M, Sasano T, Higano S, Takahashi S, Iikubo M, Kakehata S. Usefulness of heavily T(2) weighted magnetic resonance images for the differential diagnosis of parotid tumours. *Dentomaxillofac Radiol.* 2003;32:295-299.
- Healey WV, Perzin KH, Smith L. Mucoepidermoid carcinoma of salivary gland origin: classification, clinical-pathological correlation and results of treatment. *Cancer.* 1970;26:368-388.
- Spiro RH, Armstrong J, Harrison L, et al. Carcinoma of major salivary glands: recent trends. *Arch Otolaryngol Head Neck Surg.* 1989;115:316-321.
- Clode AL, Fonseca I, Santos JR, Soares J. Mucoepidermoid carcinoma of the salivary glands: a reappraisal of the influence of tumor differentiation on prognosis. *J Surg Oncol.* 1991;46:100-106.
- Weber RS, Byers RM, Petit B, Wolf P, Ang K, Luna M. Submandibular gland tumors. *Arch Otolaryngol Head Neck Surg.* 1990;116:1055-1060.
- McNaney D, McNeese MD, Guillaumondequi OM, Fletcher GH, Oswald MJ. Postoperative irradiation in malignant epithelial tumors of the parotid. *Int J Radiat Oncol Biol Phys.* 1983;9:1289-1295.
- Nascimento AG, Amaral ALP, Prado LAF, Kligerman J, Silveira TRP. Mucoepidermoid carcinoma of salivary glands: a clinicopathologic study of 46 cases. *Head Neck Surg.* 1986;8:409-417.
- Pires FR, Paes de Almeida O, Cavalcanti de Araujo V, Kowalski LP. Prognostic factors in head and neck mucoepidermoid carcinoma. *Arch Otolaryngol Head Neck Surg.* 2004;130:174-180.
- Guzzo M, Andreola S, Sirizzotti G, Cantu G. Mucoepidermoid carcinoma of the salivary glands: clinicopathologic review of 108 patients treated at the National Cancer Institute of Milan. *Ann Surg Oncol.* 2002;9:688-695.
- Boahene DKO, Olsen KD, Lewis JE, Pinheiro D, Pankratz VS, Bagniewski SM. Mucoepidermoid carcinoma of the parotid gland: the Mayo clinic experience. *Arch Otolaryngol Head Neck Surg.* 2004;130:849-856.
- Zbaren P, Schupbach J, Nuyens M, Stauffer E. Elective neck dissection versus observation in primary parotid carcinoma. *Otolaryngol Head Neck Surg.* 2005; 132:387-391.
- Rodriguez-Cuevas S, Labastida L, Baena L, Gallegos F. Risk of nodal metastases from malignant salivary gland tumors related to tumor size and grade of malignancy. *Eur Arch Otorhinolaryngol.* 1995;252:139-142.
- Frankenthaler RA, Byers RM, Luna MA, Callender DL, Wolf P, Goepfert H. Predicting occult lymph node metastasis in parotid cancer. *Arch Otolaryngol Head Neck Surg.* 1993;119:517-520.
- Medina JE. Neck dissection in the treatment of cancer of major salivary glands. *Otolaryngol Clin North Am.* 1998;31:815-821.
- Plambeck K, Friedrich RE, Bahlo M, Bartel-Friedrich S, Klapdor R. TNM staging, histopathological grading, and tumor-associated antigens in patients with a history of mucoepidermoid carcinoma of the salivary glands. *Anticancer Res.* 1999; 19:2397-2404.
- Hicks MJ, el-Naggar AK, Flaitz CM, Luna MA, Batsakis JG. Histocytologic grading of mucoepidermoid carcinoma of major salivary glands in prognosis and survival: a clinicopathologic and flow cytometric investigation. *Head Neck.* 1995; 17:89-95.
- Venook AP, Tseng A, Meyers FJ, et al. Cisplatin, doxorubicin, and 5-fluorouracil chemotherapy for salivary gland malignancies: a pilot study of the Northern California Oncology Group. *J Clin Oncol.* 1987;5:951-955.